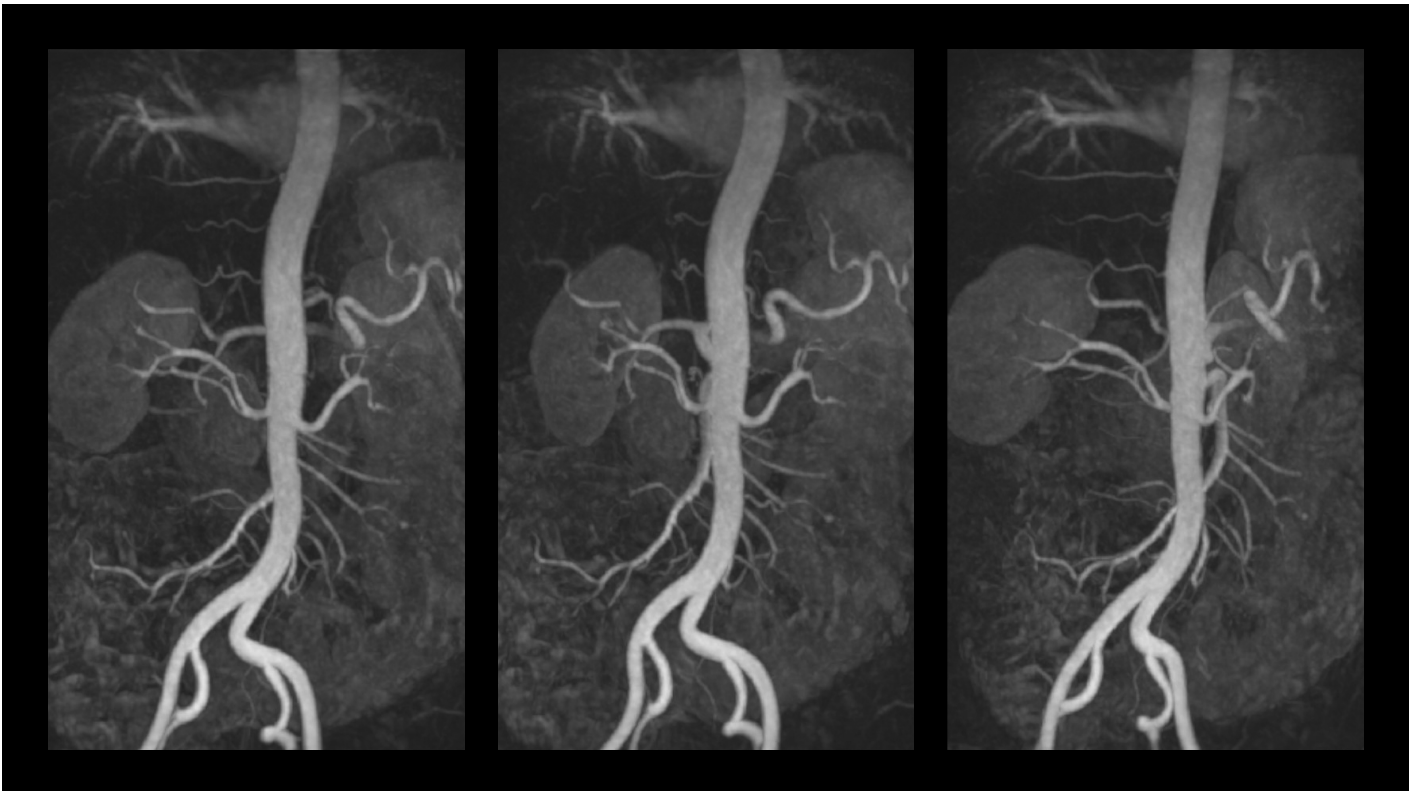



GE HealthCare

## CASE STUDY

# MRI of the renal arteries



Images and content are courtesy of:

**Prof. Dr. Wolfgang Schima, MSc**  
Diagnostic and Interventional Radiology  
Hospital Göttlicher Heiland, Vinzenz Group  
Vienna, Austria

All clinical protocols and decisions remain the responsibility of the healthcare provider. Information contained in this booklet may be abridged and should be used in alignment with institutional protocols and good clinical judgment.

[Click here for prescribing information and adverse event reporting details](#)



# MRI of the renal arteries

## Medical history of the patient

41-year-old male patient presenting with suspected malignant hypertension. “Malignant” in this condition means that this type of hypertension has a “malignant” clinical course with severe hypertension, which is refractory to medication.

## Preliminary diagnostics

Renal artery stenosis may be one cause of hypertension. No imaging has been done so far.

## Indication for MRI

An MRI examination was requested to investigate the renal arteries and rule out stenosis of the artery. Colour-coded ultrasound, in general, is not as sensitive as MRA to detect renal artery stenosis and in this particular case it is not an option (because of patient weight).

## Scan protocol includes

**MRI: 3T**

1. Coronal balanced SSFP (T2/T1 weighted)
2. Axial 3D T1 GE Dixon
3. MRA of the renal arteries with MIP reconstruction
4. Axial 3D T1 GE Dixon after contrast injection

## Injection protocol

Patient weight 115 kg

### GBCA injection

Gadobutrol 0.1 mmol/kg	9 mL – 2 mL/sec
------------------------	-----------------

0.9 % NaCl	40 mL
------------	-------

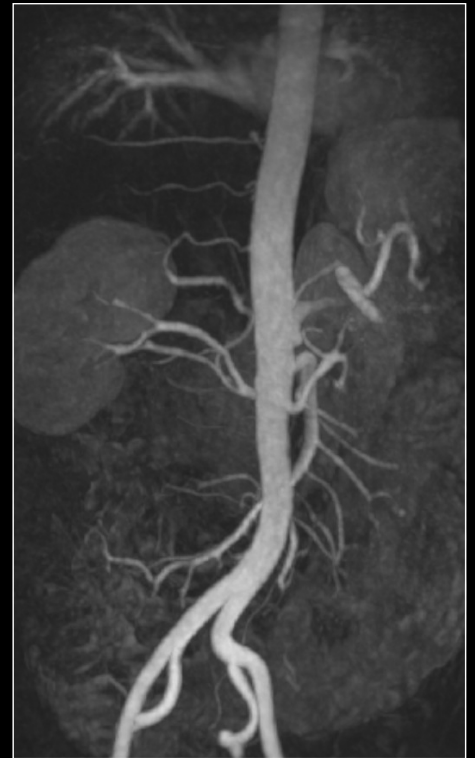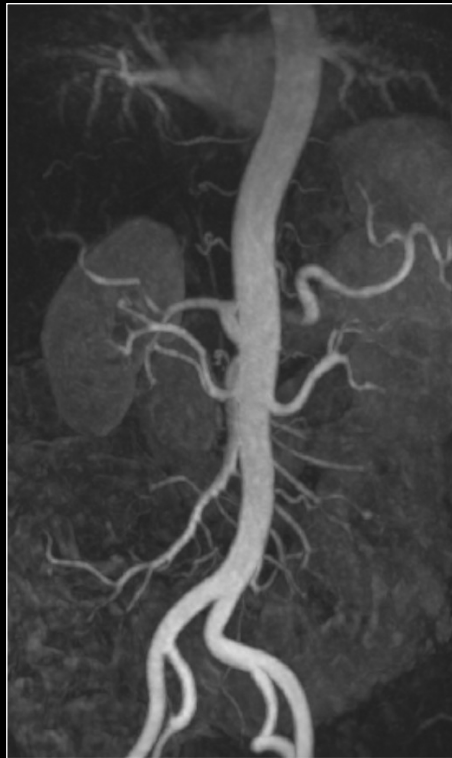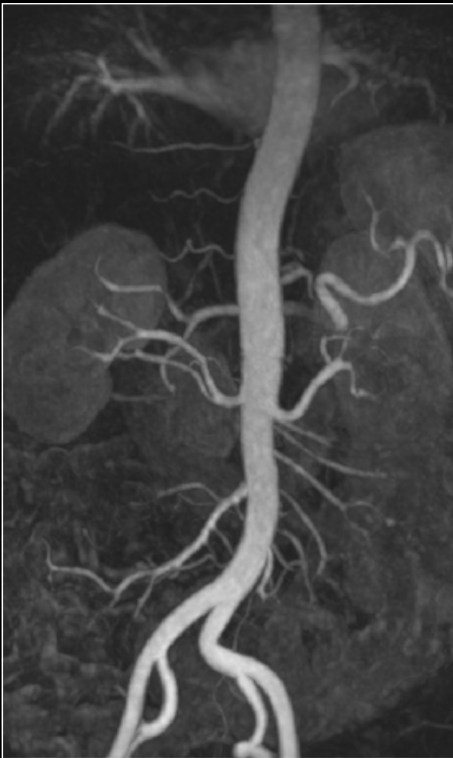Administration mode	With injector
---------------------	---------------



## Findings of the MRI examination

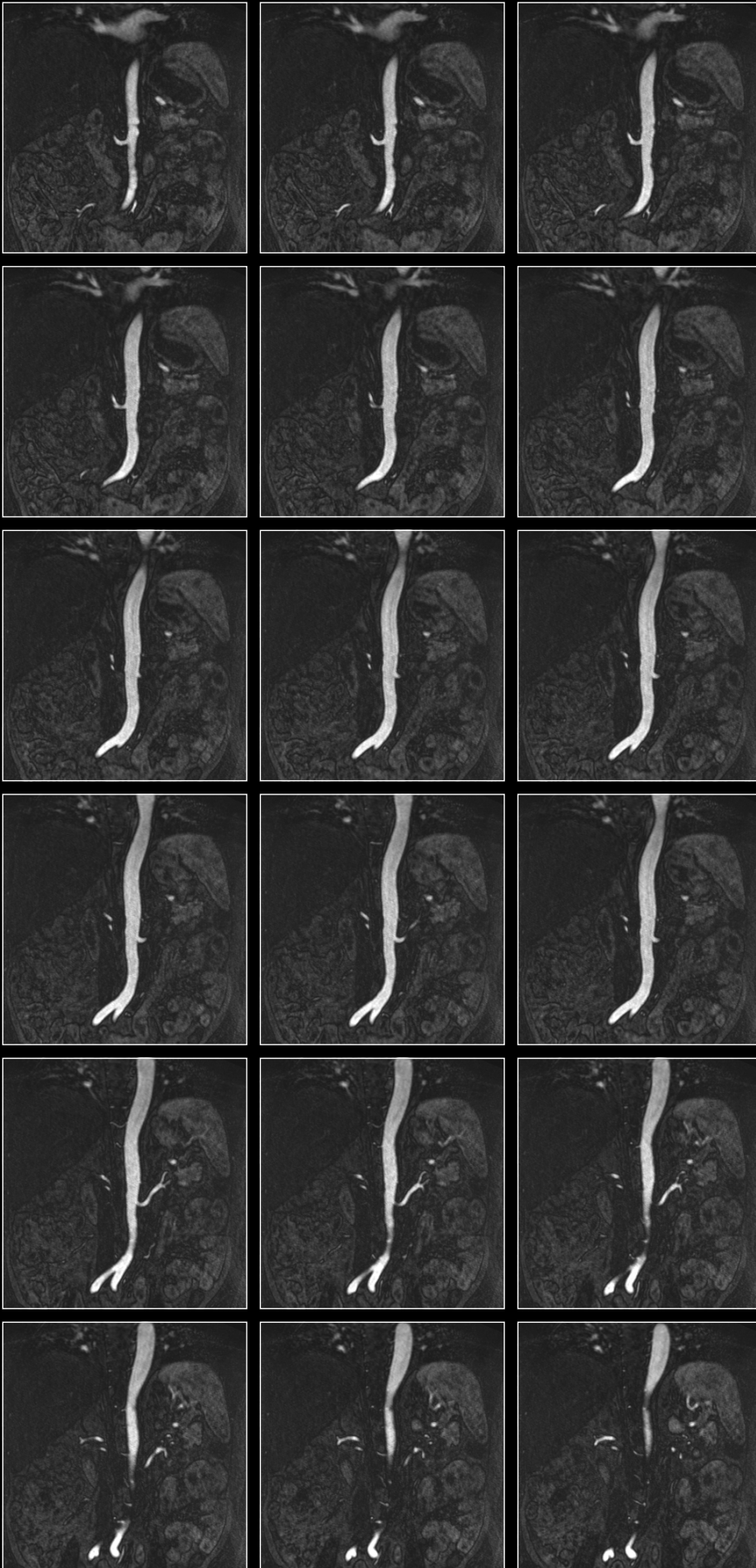
The MRA is showing normal arteries.

3D T1 MRA sequence acquired in coronal plane



**MIP reconstruction of the MRA sequence:**  
Showing normal renal arteries

Raw images of the 3D MRA sequence acquired in coronal plane



**MRA raw data:**

MRA nicely shows the normal renal arteries, no stenoses, no accessory (supernumerary) renal arteries present.



## Diagnosis and therapy or follow-up:

Patient with malignant hypertension and normal renal arteries (no stenosis).  
Intensive medical therapy for hypertension is suggested, no intervention is needed.

### Abbreviations:

GE: gradient echo

MIP: maximum intensity projection

MRA: MR angiography

MRI: magnetic resonance imaging

SSFP: Steady-State Free Precession

GE Healthcare Limited, Pollards Wood, Nightingales Lane,  
Chalfont St Giles, Buckinghamshire, England HP8 4SP  
[www.gehealthcare.com](http://www.gehealthcare.com)

© 2025 GE Healthcare

GE is a trademark of General Electric Company used under trademark license.

02-2025 JB31259XX/JB04012UK/DGT/OS UK