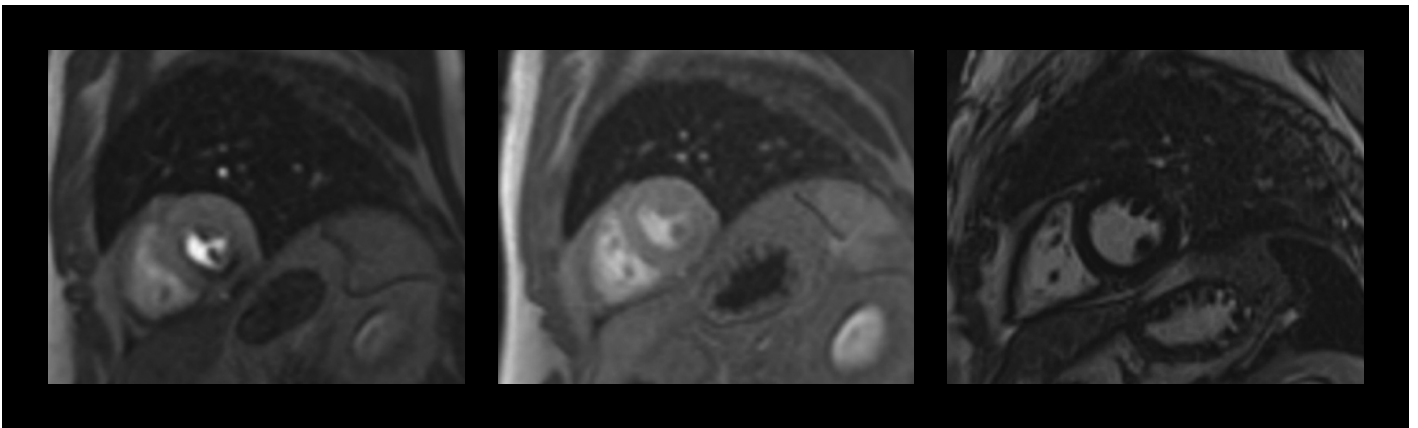


CASE STUDY

Cardiac MRI with stress/rest perfusion and late gadolinium enhancement (LGE)



Images and content are courtesy:

Prof. PD Dr. Agnes Mayr

University Hospital of Radiology

Medical University Innsbruck, Austria

All clinical protocols and decisions remain the responsibility of the healthcare provider. Information contained in this booklet may be abridged and should be used in alignment with institutional protocols and good clinical judgment.



Cardiac MRI with stress/rest perfusion and late gadolinium enhancement (LGE)

Medical history of the patient

56-year-old male patient with cardiovascular risk factors such as hypercholesterolemia and nicotine abuse (40-pack years), presenting with chest pain and dyspnea under exertion that he has been experiencing for several weeks.

Preliminary diagnostics

The patient underwent an ECG that showed a ST segment depression pattern before age-appropriate maximum load.

The echocardiography was unremarkable with preserved biventricular systolic function.

Indication for MRI

Further examinations concluded that the patient suffers from a diffuse 3-vessel coronary heart disease with stenoses in the proximal right coronary artery and in the middle left anterior descending artery. Cardiac MRI with stress perfusion has been prescribed to determine the haemodynamic relevance of those stenoses and to assess myocardial viability.

Scan protocol includes **MRI: 1.5T**

1. Short axis Cine sequence (balanced SSFP)
2. Short axis **stress perfusion** sequence
3. 3 chamber view Cine sequence (balanced SSFP)
4. 4 chamber view Cine sequence (balanced SSFP)
5. Long axis view Cine sequence (balanced SSFP)
6. Short axis **rest perfusion** sequence
7. Long axis and 4 chamber LGE sequence
8. Short axis LGE sequence

Injection protocol

Patient weight 83 kg

First GBCA injection for stress perfusion

Gadobutrol 0.1 mmol/kg	8.3 mL – Flow 3mL/sec
0.9 % NaCl	20 mL
Pharmacological stress agent:	5 mL over 10 sec (manual injection)
Rapiscan™ (regadenoson) flushed with NaCl.	
Reversal of stress agent	not used.
Start of MR stress examination:	90 sec post-injection of Rapiscan

Second GBCA injection for rest perfusion

Gadobutrol 0.1 mmol/kg	8.3 mL – Flow 3 mL/sec
0.9 % NaCl	20 mL
Start of LGE sequences post-administration of this second GBCA injection	3 minutes



Findings of the MRI examination

MRI examination shows evidence of stress induced ischaemia of the left ventricular posterior wall at basal to apical segments (5/16 AHA segments) with right ventricular posterior wall involvement. No infarction scars visible on the MRI. The vitality of all coronary artery territories is completely preserved.

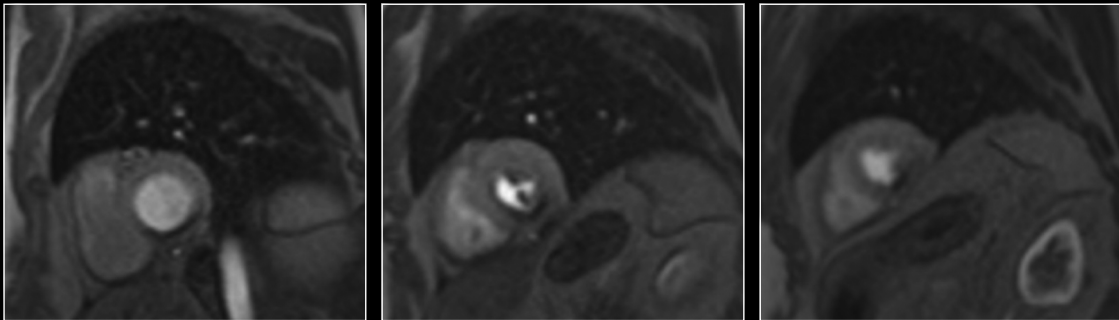
The biventricular systolic function is normal (LVEF: 60%, RVEF: 48%); no regional wall motion disorder.

Basal

Mid cavity

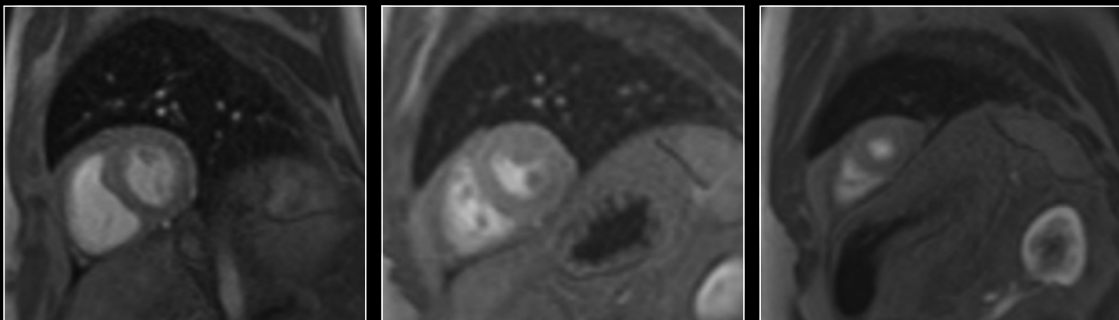
Apical

First injection of Gadobutrol 0.1 mmol/kg

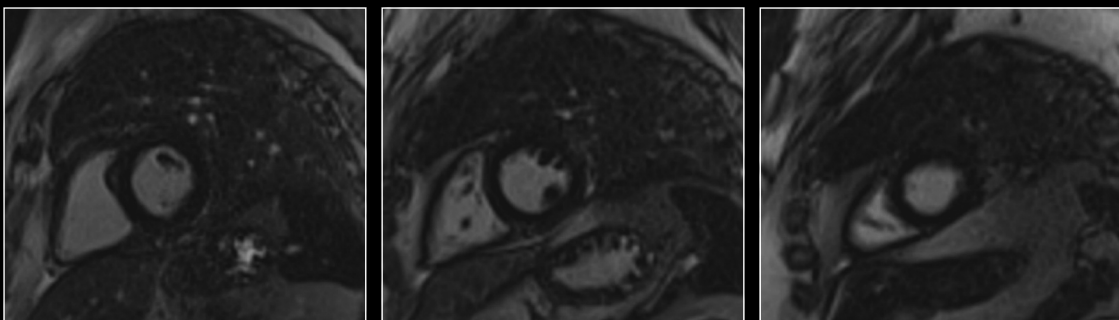


Dynamic first pass perfusion at stress in the short-axis plane:
Showing large perfusion defect in the territory of the right coronary artery.

Second injection of Gadobutrol 0.1 mmol/kg



Dynamic first pass perfusion at rest in the short-axis plane:
Showing no perfusion defect in the territory of the right coronary artery.



Late gadolinium enhancement in the short-axis plane:
Showing no scar.



Diagnosis and therapy or follow-up:

Stress induced ischaemia of the LV posterior wall at basal to apical segments (5/16 AHA segments).

Stenting of the proximal right coronary artery (RCA) stenosis is the suggested therapy.

Abbreviations:

AHA: American Heart Association
DCE-MRI: Dynamic Contrast-Enhanced MRI
ECG: electrocardiogram
GBCA: gadolinium-based contrast agent
LV: left ventricular
LVEF: left ventricular ejection fraction
MDE: myocardial delayed enhancement
MR: magnetic resonance
MRI: magnetic resonance imaging
RVEF: right ventricular ejection fraction
ST: ST-segment
SSFP: steady-state free precession
RCA: right coronary artery

GE Healthcare Limited, Pollards Wood, Nightingales Lane,
Chalfont St Giles, Buckinghamshire, England HP8 4SP
www.gehealthcare.com