

CERIANNA™
(FLUOROESTRADIOL F 18) INJECTION

Cerianna (FES) PET Use in Challenging Cases



GE HealthCare

Important Safety Information

Important Safety Information

INDICATIONS AND USAGE:

CERIANNA is indicated for use with positron emission tomography (PET) imaging for the detection of estrogen receptor (ER)-positive lesions as an adjunct to biopsy in patients with recurrent or metastatic breast cancer.

Limitations of Use:

Tissue biopsy should be used to confirm recurrence of breast cancer and to verify ER status by pathology. CERIANNA is not useful for imaging other receptors, such as human epidermal growth factor receptor 2 (HER2) and the progesterone receptor (PR).

CONTRAINDICATIONS

None.

WARNINGS AND PRECAUTIONS

Risk of Misdiagnosis

Inadequate Tumor Characterization and Other ER-Positive Pathology: Breast cancer may be heterogeneous within patients and across time. CERIANNA images ER and is not useful for imaging other receptors such as HER2 and PR. The uptake of fluoroestradiol F 18 is not specific for breast cancer and may occur in a variety of ER-positive tumors that arise outside of the breast, including from the uterus and ovaries. Do not use CERIANNA in lieu of biopsy when biopsy is indicated in patients with recurrent or metastatic breast cancer.

False Negative CERIANNA Scan: A negative CERIANNA scan does not rule out ER-positive breast cancer. Pathology or clinical characteristics that suggest a patient may benefit from systemic hormone therapy should take precedence over a discordant negative CERIANNA scan.

Important Safety Information (cont'd)

Radiation Risks: Diagnostic radiopharmaceuticals, including CERIANNA, expose patients to radiation. Radiation exposure is associated with a dose-dependent increased risk of cancer. Ensure safe drug handling and patient preparation procedures (including adequate hydration and voiding) to protect patients and health care providers from unintentional radiation exposure.

Pregnancy Status: Assessment of pregnancy status is recommended in females of reproductive potential before administering CERIANNA.

USE IN SPECIFIC POPULATIONS

Pregnancy

Risk Summary: All radiopharmaceuticals, including CERIANNA, have the potential to cause fetal harm depending on the fetal stage of development and the magnitude of radiation dose. Advise a pregnant woman of the potential risks of fetal exposure to radiation from administration of CERIANNA.

There are no available data on CERIANNA use in pregnant women. No animal reproduction studies using fluoroestradiol F 18 have been conducted to evaluate its effect on female reproduction and embryo-fetal development.

The estimated background risk of major birth defects and miscarriage for the indicated populations is unknown. All pregnancies have a background risk of birth defects, loss, or other adverse outcomes. In the U.S. general population, the estimated background risk of major birth defects and miscarriage in clinically recognized pregnancies is 2-4% and 15-20%, respectively.

Lactation

Risk Summary: There are no data on the presence of fluoroestradiol F 18 in human milk, or its effects on the breastfed infant or milk production. Lactation studies have not been conducted in animals. Advise a lactating woman to avoid breastfeeding for 4 hours after CERIANNA administration in order to minimize radiation exposure to a breastfed infant.

Important Safety Information (cont'd)

Pediatric Use: The safety and effectiveness of CERIANNA in pediatric patients have not been established.

Geriatric Use: Clinical studies of fluoroestradiol F 18 injection did not reveal any difference in pharmacokinetics or biodistribution in patients aged 65 and over.

DRUG INTERACTIONS

Systemic Endocrine Therapies that Bind to ER

Drugs that bind to the ER, including SERMs and SERDs, may compete with the binding of fluoroestradiol F18 and may reduce detection of ER-positive lesions with CERIANNA.

Before administration of CERIANNA, discontinue drugs that bind to the ER, such as SERMs and SERDs, for at least 5 biological half-lives: (e.g. elacestrant for 11 days, tamoxifen for 8 weeks and fulvestrant for 28 weeks).

ADVERSE REACTIONS: In Clinical Trials (n=1207) the most common adverse reactions seen occurred at a rate < 1% were injection-site pain and dysgeusia.

To report SUSPECTED ADVERSE REACTIONS, contact GE HealthCare at 800 654 0118 (option 2 then option 1) or by email at GPV.drugsafety@gehealthcare.com or FDA at 800 FDA 1088 or www.fda.gov/medwatch.

RESOURCES

Customer Service: 800-292-8514

Cerianna Support Center: 833-946-6392

Medical Affairs for Clinical and Scientific Support: 800-654-0118. (option 2, then option 3) or medical.affairs@gehealthcare.com

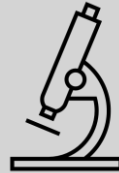gehealthcare.com

For full Prescribing Information, please scan the QR Code



Clinical challenges of diagnosing and treating ER+ recurrent and metastatic breast cancer

Imaging the ER+ status vs. glucose metabolism can lead to clearer diagnoses for these patients.



[Learn more](#)

FES PET/CT offers another imaging option for patients with disease that is occult or hard to assess on standard imaging.



[Learn more](#)

The specificity of FES PET/CT for imaging the ER may be leveraged for specific applications where knowledge of ER expression may guide treatment⁶.



[Learn more](#)

FES PET/CT may help distinguish an ER+ breast cancer from an ER-negative malignancy in patients in which more than one type of malignancy is known or may be present⁷.



[Learn more](#)

FES PET/CT may distinguish recurrent neoplasm from RT sequelae, thus facilitating subsequent treatment planning⁵.

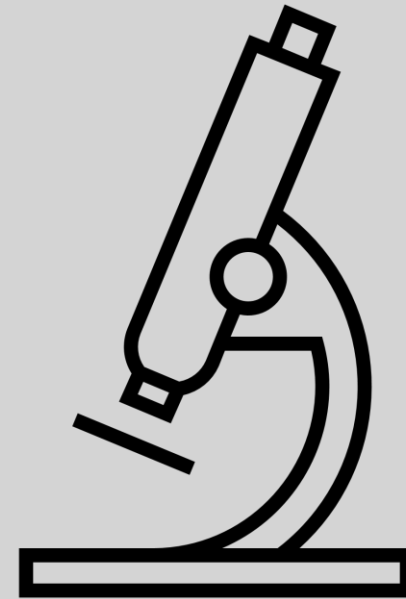


[Learn more](#)

FDG, fluorodeoxyglucose; FES, fluoroestradiol; ER+, estrogen receptor positive; PET, positron emission tomography; CT, computed tomography; RT, radiation therapy.

Key challenge:

FDG uptake is generally low in low-grade tumors, ER+ disease, and lobular histologic type¹. This may lead to reduced sensitivity resulting in understaging and incomplete assessment of disease burden.²



FDG, fluorodeoxyglucose; ER+, estrogen receptor positive.

Upstaging a patient with ER+ invasive lobular carcinoma



Scan to review
publication abstract

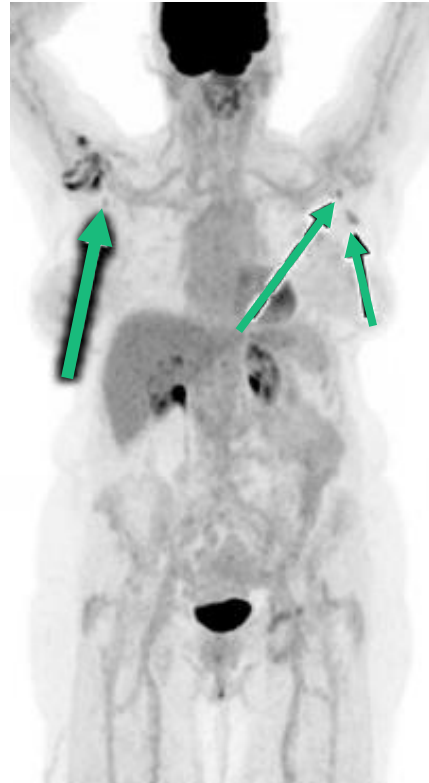
Case details⁸

- 78-year-old woman with a new diagnosis of invasive lobular carcinoma (ILC), grade II (ER+, PR+, HER2-)
- She initially presented with a left breast primary and left axillary lymph node metastasis (biopsy-confirmed)
- Staging FDG PET/CT:
 - Mild FDG uptake at primary tumor
 - Mild FDG uptake in left axillary lymph nodes
 - Indeterminate, mild FDG uptake in right axillary lymph nodes

FES PET/CT was ordered to assess the ER+ disease burden given ILC often shows low FDG avidity and there was suspicion for metastatic disease bilaterally.

ER+, estrogen receptor positive; PR+, progesterone receptor positive; HER2, human epidermal growth factor receptor 2; FDG, fluorodeoxyglucose; FES, fluoroestradiol; PET, positron emission tomography; CT, computed tomography; ILC, invasive lobular carcinoma

FDG PET MIP



FES PET MIP

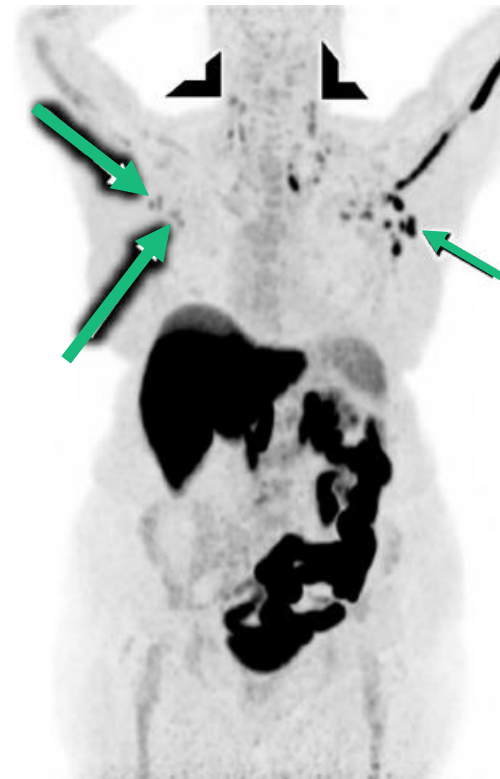


Image Credit: Rehman et al.

Interpretation of Images⁸:

- **FDG PET:** Mild uptake observed in left axillary lymph nodes, consistent with known metastatic disease. Indeterminate mild uptake in right axillary lymph nodes, raising suspicion for contralateral involvement
- **FES PET:** Abnormal uptake in right axillary lymph nodes and bilateral cervical lymph nodes, revealing previously undetected distant ER+ metastases

Importance of FES imaging⁸:

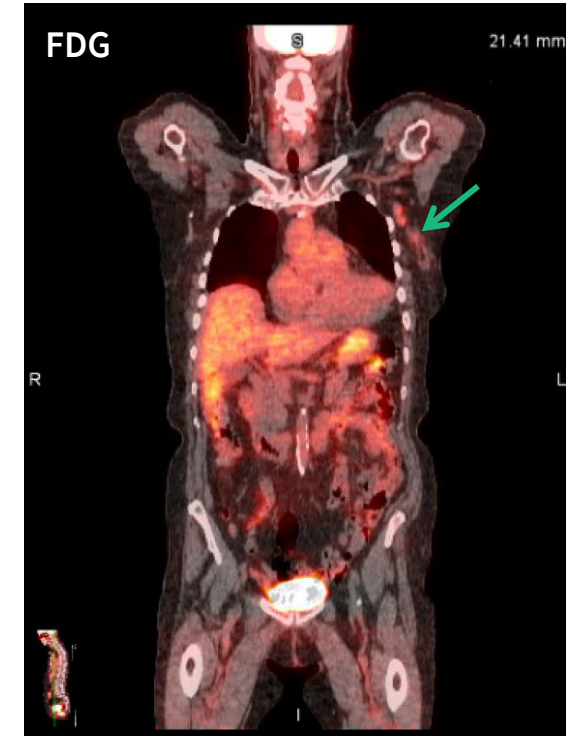- Identified contralateral ER+ metastases and cervical nodes which were occult on FDG PET/CT
- **Patient's stage changed from II to IV, altering her treatment plan**

FDG, fluorodeoxyglucose; FES, fluoroestradiol; MIP, maximum intensity projection; ER+, estrogen receptor positive; PET, positron emission tomography; CT, computed tomography

Cerianna (FES) PET in a post surgical patient

Case details

- 79-year-old female with history below:
 - Right breast cancer (invasive lobular carcinoma, ER/PR+, HER2 negative) s/p right total mastectomy (2012)
 - Left breast cancer (invasive lobular carcinoma, ER/PR+, HER2 negative) s/p left total mastectomy (2015)
 - Right axillary recurrence (3/5 LN+), completed radiation (2018)
- Presented again in 2021 with new left axillary recurrence: Grade 1 ILC (ER+,PR-, HER2-)
- FDG PET/CT prior to surgery revealed soft tissue changes with low grade uptake in left axillary LN, negative for distant metastatic disease
- Patient underwent left axillary mass excision and left axillary lymph node dissection
 - Final pathology revealed a 1.2 cm chest wall mass and 13/20 axillary lymph nodes that were positive for recurrent ER+ breast cancer

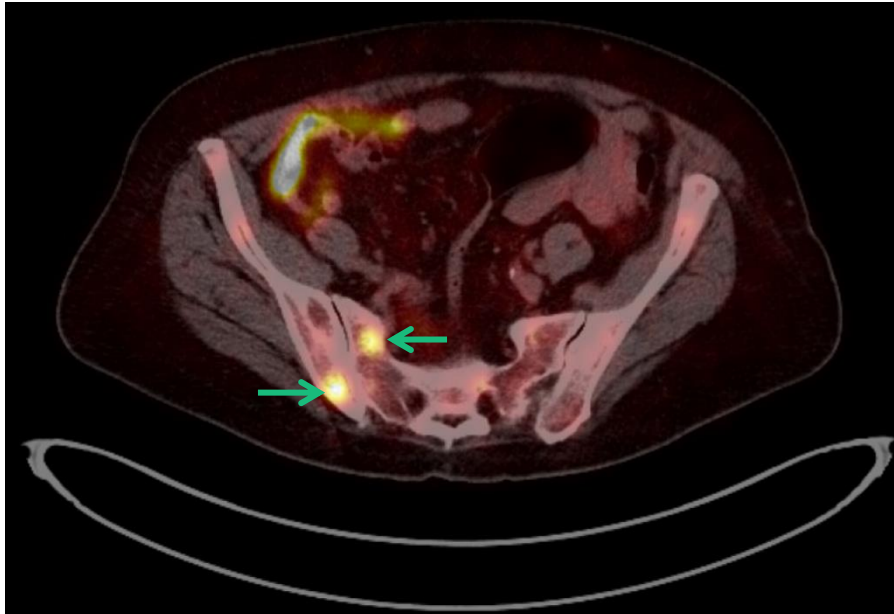


Cerianna (FES) PET/CT was ordered based on concern for metastatic ER+ breast cancer given significant axillary nodal disease burden which was not appreciated on the FDG PET/CT.

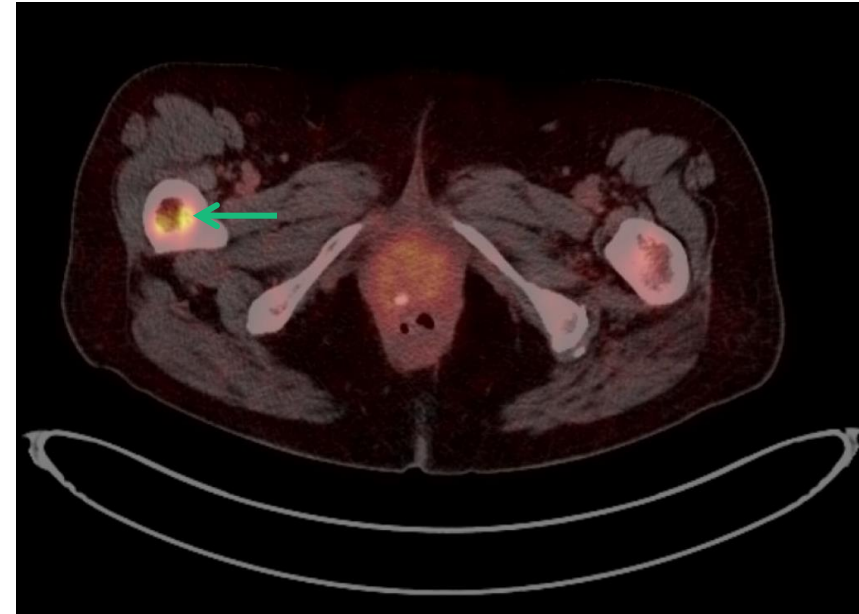
FES, fluoroestradiol; PET, positron emission tomography; ER, estrogen receptor; PR, progesterone receptor; HER2, human epidermal growth factor receptor 2; LN, lymph node, ILC, invasive lobular carcinoma; MRI, magnetic resonance imaging; FDG, fluorodeoxyglucose; CT, computed tomography, cm, centimeter; +, positive.

Image credit: Dr. Valerie Gorman, Baylor Scott and White Health.

FES PET/CT: Right sacrum



FES PET/CT: Right femur



Interpretation:

- Cerianna (FES) PET/CT: Demonstrates multiple osseous ER+ metastases

Importance:

- Patient was upstaged to stage IV and started on endocrine therapy plus a CDK 4/6 inhibitor
- Cerianna (FES) PET/CT helped provide a clear diagnosis which led to a more confident treatment plan for the patient

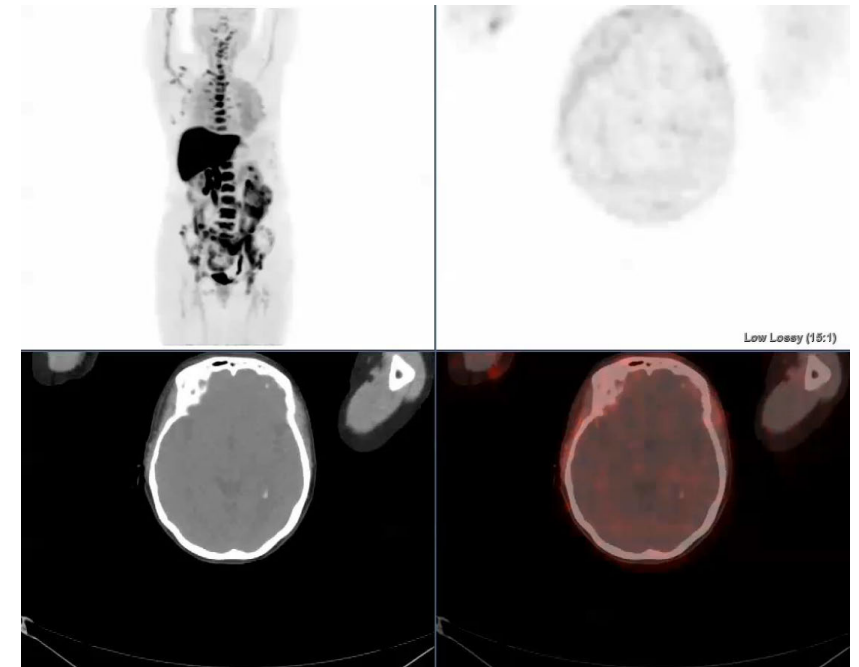
FES, fluoroestradiol; PET, positron emission tomography; CT, computed tomography; ER+, estrogen receptor positive; CDK 4/6, cyclin dependent kinase.

Image credit: Dr. Valerie Gorman, Baylor Scott and White Health.

FES PET may help close the gap in diagnostic dilemmas

Case details⁹

- 67-year-old woman with invasive lobular breast cancer
- FDG PET/CT demonstrated few mild tracer foci, equivocal for active malignancy



FES PET/CT

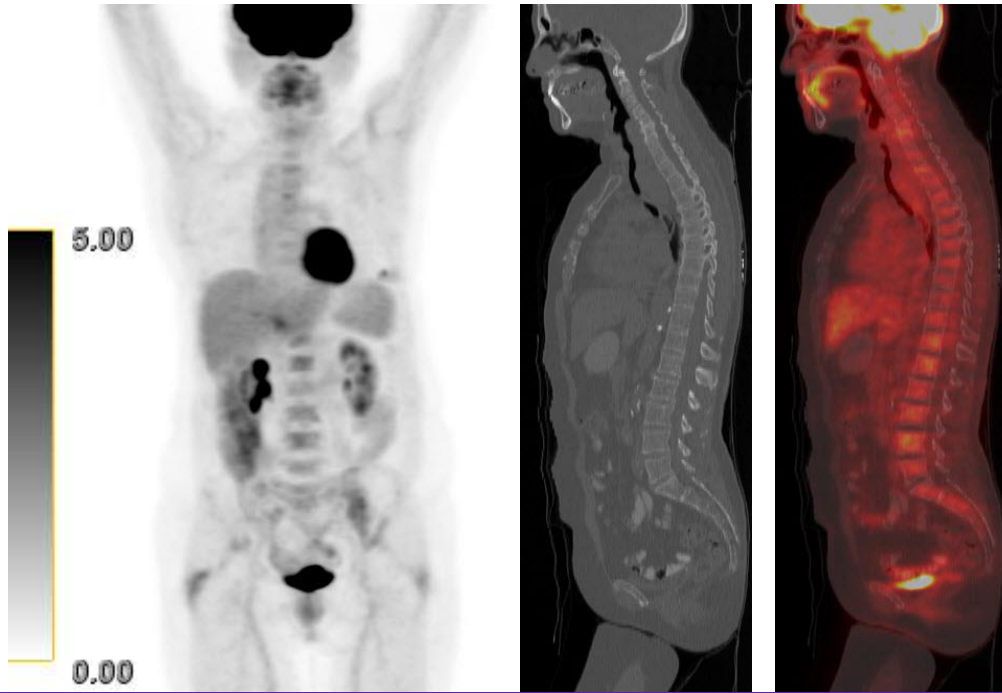
FES PET/CT was ordered as part of a clinical trial comparing FDG and FES PET in metastatic invasive lobular breast cancer patients.

*The F18 fluoroestradiol administered in this study was not equivalent to the FDA-approved formulation of Cerianna.

FES, fluoroestradiol; FDG, fluorodeoxyglucose; PET, positron emission tomography; CT, computed tomography.

Image credit: Dr. Gary Ulaner, Hoag Family Cancer Institute.

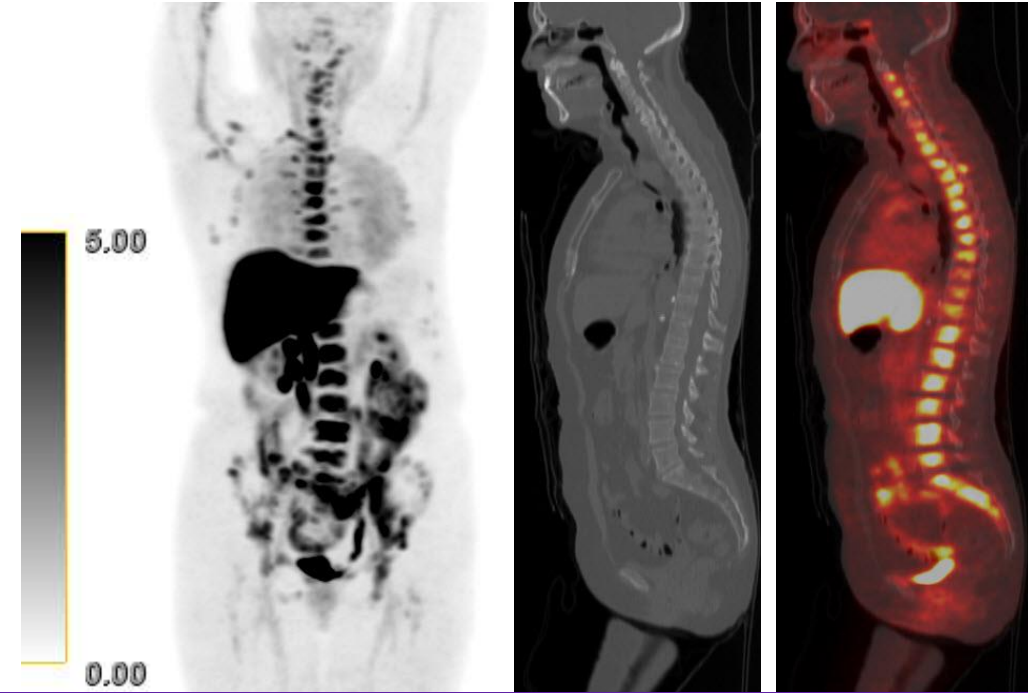
FDG PET/CT



Interpretation⁹:

- FDG PET/CT demonstrated few mild tracer foci, equivocal for active malignancy
- FES PET/CT demonstrates widespread ER+ osseous foci

FES PET/CT



Importance⁹:

- FES PET/CT may demonstrate ER+ osseous lesions not detected on FDG PET or CT
- Subsequent biopsy confirmed bone metastasis

*The F18 fluoroestradiol administered in this study was not equivalent to the FDA-approved formulation of Cerianna.

FDG, fluorodeoxyglucose; PET, positron emission tomography; CT, computed tomography; FES, fluoroestradiol; ER+, estrogen receptor positive.

Image credit: Dr. Gary Ulaner, Hoag Family Cancer Institute.

[Back to the top](#)

Key challenge:

Tumors of lobular histology tend to be diffuse with a predilection for serosal surfaces as metastatic sites such as GI tract, ovaries, peritoneum, retroperitoneum, periorbital and leptomeninges. These distinct sites and net-like spread can make extent of disease difficult to assess by conventional imaging, including FDG PET.²



FES PET detects intraorbital ER+ metastases in a patient with ILC



Scan to review
publication abstract

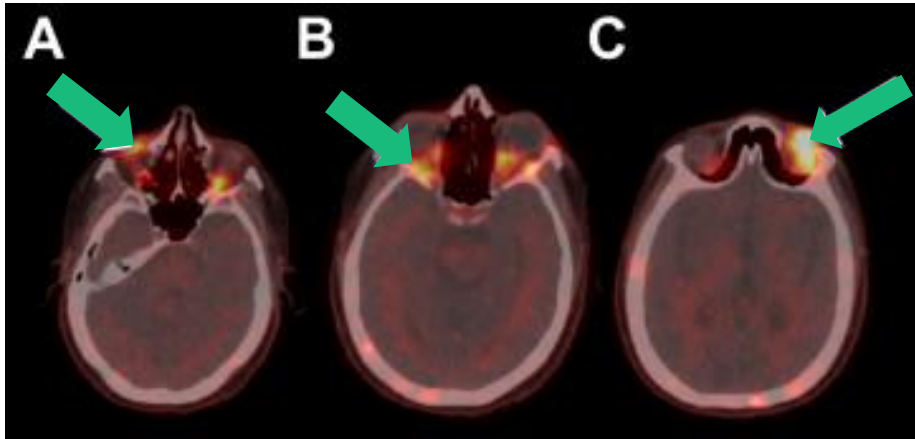
Case details¹⁰

- 63-year-old female with a history of invasive lobular carcinoma (ILC), grade 2, ER 95%, PR 90%, Her2/neu 0%
- Initial treatment:
 - Right lumpectomy and axillary lymph node dissection, which demonstrated 4.0 cm ILC with 15 of 17 positive ALNs
 - Completion mastectomy subsequently revealed 1.5 cm of additional disease (ILC)
 - She underwent adjuvant chemotherapy, post-mastectomy radiation, and 5 years of anastrozole
- One month following discontinuation of her AI, she presented with suspected recurrence

Cerianna (FES) PET was ordered to evaluate extent of ER+ breast cancer given the suspected recurrence and lobular histology.

FES, fluoroestradiol; ER, estrogen receptor; ILC, invasive lobular carcinoma; PR, progesterone receptor; HER2, human epidermal growth factor receptor 2; FDG, fluorodeoxyglucose; PET, positron emission tomography; CT, computed tomography; ER+, estrogen receptor positive; cm, centimeter; ALN, axillary lymph node; AI, aromatase inhibitor.

FES PET



MRI

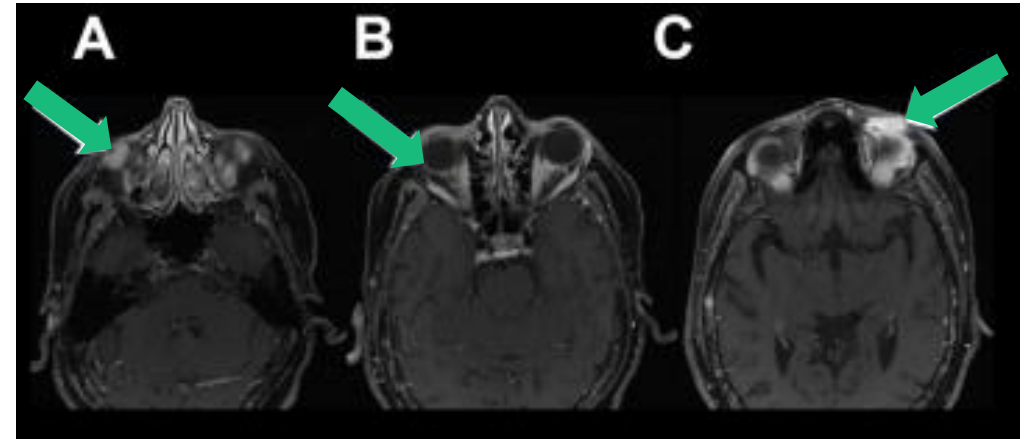


Image Credit: Bodapati et al.

Interpretation¹⁰:

- FES PET/CT demonstrated increased activity involving soft tissue nodules in the left superior orbit, right inferior orbit and bilateral extraocular muscles, and numerous foci in the skeleton
- Abnormal FES activity correlated with brain MRI findings, which were consistent with infiltrative orbital metastatic disease

Importance¹⁰:

- She was started on fulvestrant and palbociclib and was scheduled for radiation to her orbital metastases
- **FES PET may more accurately assesses the intracranial and intraorbital compartments in patients with ER+ cancers than FDG PET due to lack of physiologic background activity in these regions**

FES, fluoroestradiol; PET, positron emission tomography; CT, computed tomography; MRI, magnetic resonance imaging; ER, estrogen receptor; FDG, fluorodeoxyglucose.

FES PET identifies gastric and retroperitoneal ER+ disease in a patient with ILC



Scan to review
publication abstract



Case details^S

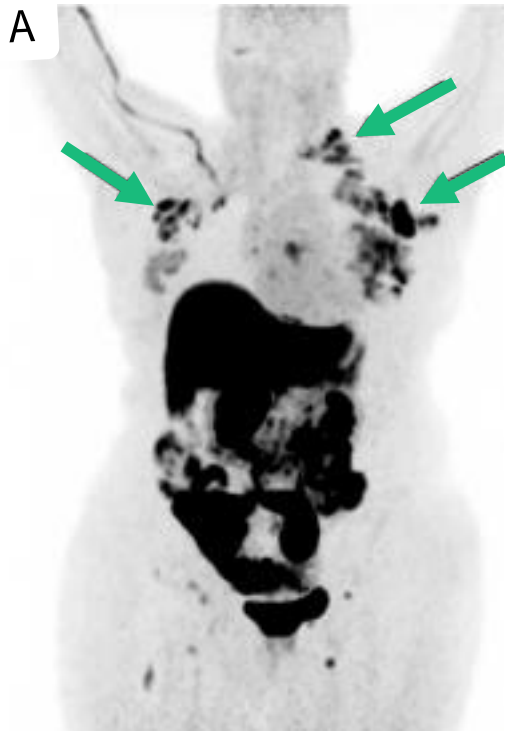- 65-year-old woman with recently diagnosed left breast ER+ invasive lobular carcinoma and biopsy-proven left axillary nodal metastases
- Staging FDG PET performed at an outside hospital (images unavailable to the ordering provider) reported FDG avid left breast cancer with FDG avid left axillary and internal mammary nodal metastases
- Additional reported findings included indeterminate non-FDG avid retroperitoneal soft tissue, a non-FDG avid left inguinal lymph node, and a few non-FDG avid, mildly enlarged left cervical nodes of uncertain significance

FES PET/CT was performed to evaluate ER+ status of the equivocal findings on FDG PET/CT.


FES, fluoroestradiol; PET, positron emission tomography; ER+, estrogen receptor positive; ILC, invasive lobular carcinoma; FDG, fluorodeoxyglucose.



FES PET MIP

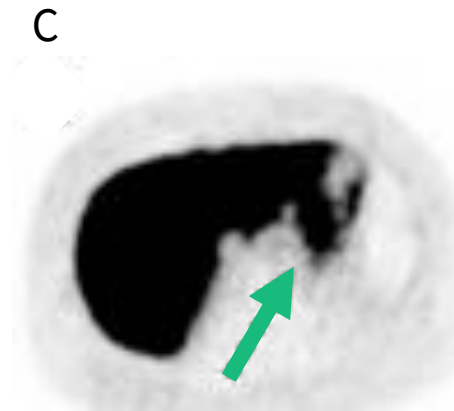


Bilateral axillary



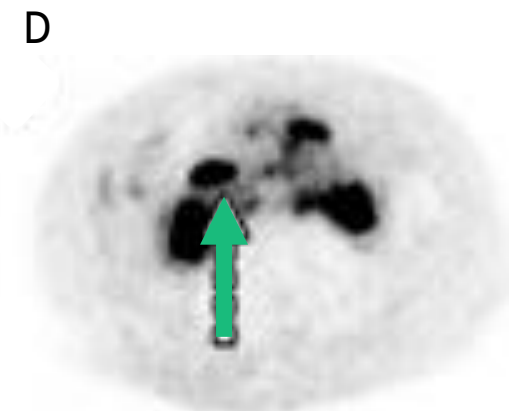
Abnormal FES uptake was seen in multiple muscle metastases (none of which were reported on outside FDG PET/CT).

Upper abdomen



Abnormal FES uptake seen in the gastric wall, also not reported on outside FDG PET/CT

Retroperitoneal (RP)



Abnormal FES uptake seen in the indeterminate retroperitoneal soft tissue, confirming ER+ metastatic disease. Confluent mesenteric lymphadenopathy correlating to the non-FDG avid RP soft tissue mass.

Interpretation⁶:

- FES PET/CT revealed FES avid left breast primary neoplasm with widely metastatic FES avid lymphadenopathy (left cervical, bilateral axillary, internal mammary, gastrohepatic, mesenteric, retroperitoneal, pelvic, and inguinal)

FES, fluoroestradiol; PET, positron emission tomography; MIP, maximum intensity projection, FDG, fluorodeoxyglucose, ER+, estrogen receptor positive; MR, magnetic resonance; ER, estrogen receptor.

Importance⁶:

- FES PET helped confirm ER+ metastatic disease in this patient when FDG was negative for distant disease
- **FES PET may help accurately identify ER+ lobular breast cancer metastases, even in sites that may be difficult to image with conventional imaging**

[Back to the top](#)

Key Challenge:

Some patients with ER+ breast cancer will progress quickly and develop endocrine resistance. Loss of ER is one principal cause of resistance to endocrine therapy and may be difficult to identify across all sites in a patient with metastatic disease.³



FES PET helped reinforce treatment strategy



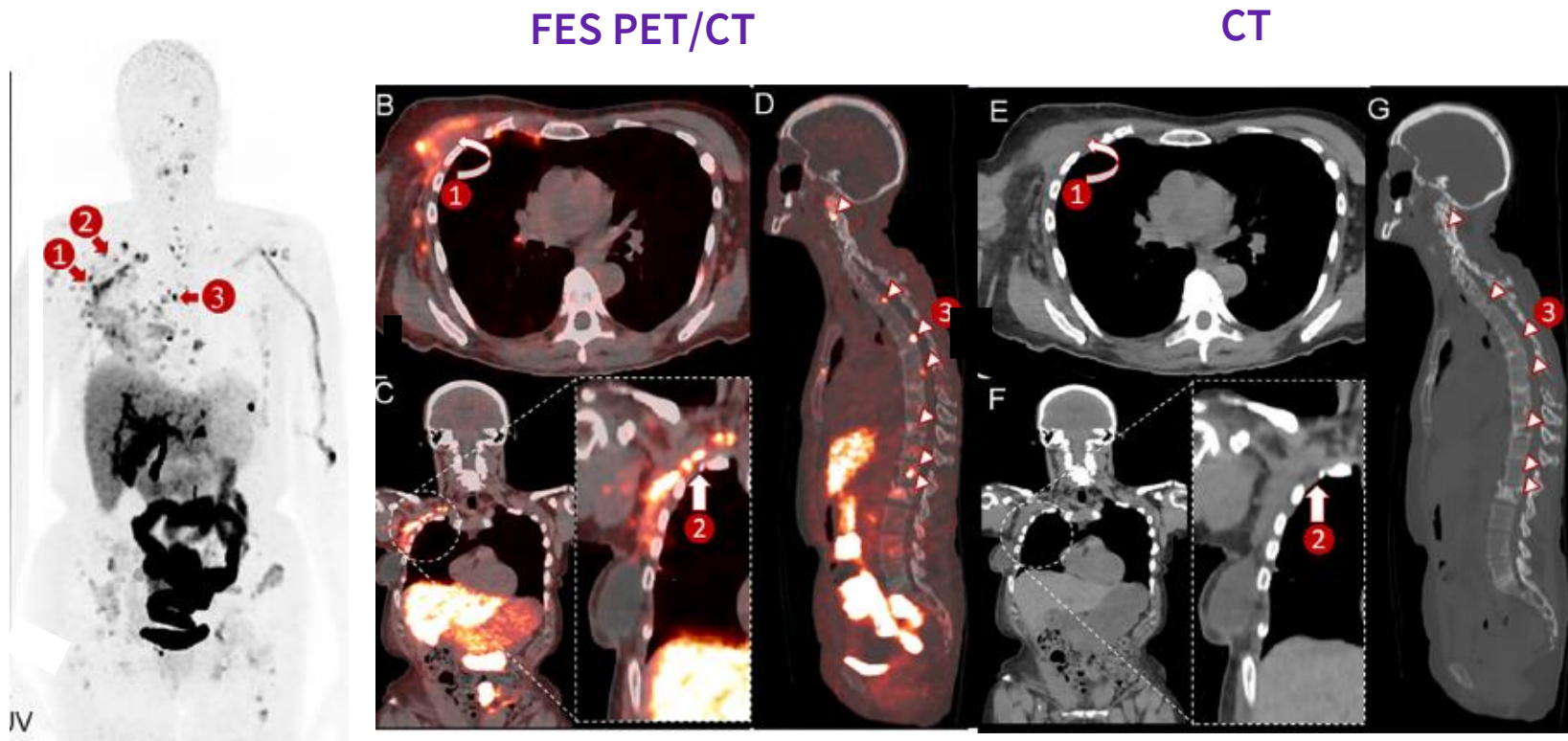
Scan to review
publication abstract

Case details

- 60-year-old woman with right breast cancer (intermediate grade, ER+, PR+, HER2-)
- She underwent surgery with clear margins and negative sentinel lymph nodes and opted against any adjuvant treatment
- CT evaluation 6 months later due to bone pain revealed an infiltrative mass in the right anterior chest wall within the mastectomy bed and multiple mixed lytic and sclerotic bone lesions raising concerns for a recurrence
- Subsequently, the patient underwent CT-guided core biopsy of the iliac bone, confirming metastatic breast cancer of (ER+,PR+, HER2-)

FES PET scan was ordered to assess ER+ status given rapid progression to metastatic disease and endocrine therapy being considered as the next line of therapy.

FES, fluoroestradiol; CT, computed tomography; PET, positron emission tomography; ER+, estrogen receptor positive; PR+, progesterone receptor positive; HER2-, human epidermal growth factor receptor 2 negative.



Interpretation¹¹:

- Widespread FES positive lesions in the right chest wall right axillary and mediastinal lymph nodes, and axial and appendicular skeleton

Importance¹¹:

- This information not only determined the overall extent of ER+ metastatic disease but also reinforced the strategy for treating her disease with endocrine therapy
- This case shows how FES PET may be helpful in identifying ER+ disease extent when patients progress rapidly

FES, fluoroestradiol; PET, positron emission tomography; CT, computed tomography; ER+, estrogen receptor-positive.

Image credit: Zhou et. al

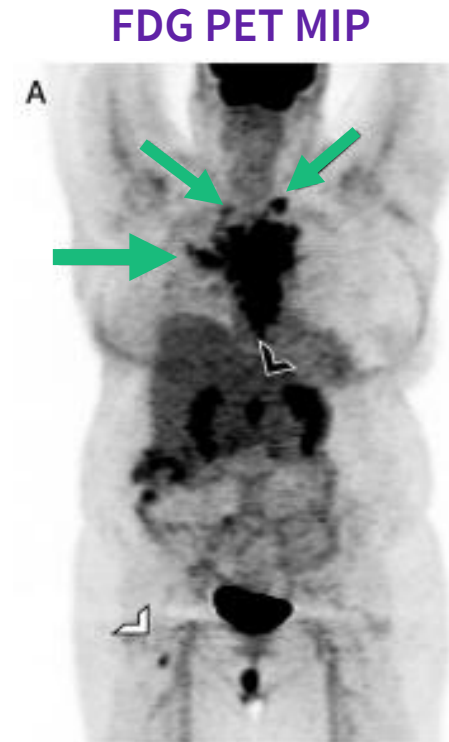Patient presents with recurrent metastatic low ER+ breast cancer



Scan to review
publication abstract

Case details⁶

- 66-year-old woman with history of right ER/PR+ invasive ductal carcinoma post breast conservation therapy, now with recently discovered metastatic disease, biopsy-proven with low ER positivity (2%)
- FDG PET/CT identified multiple sites of metastatic disease including the bilateral supraclavicular and mediastinal lymph nodes, retroperitoneal lymph nodes, liver, and bones (including right femur)



Cerianna (FES) PET scan was obtained to assess ER+ status of disease and evaluation for endocrine therapy.

ER+, estrogen receptor-positive; FES, fluoroestradiol; CT, computed tomography; PET, positron emission tomography; FDG, fluorodeoxyglucose; PR+, progesterone receptor positive.

Image Credit: O'Brien et al.

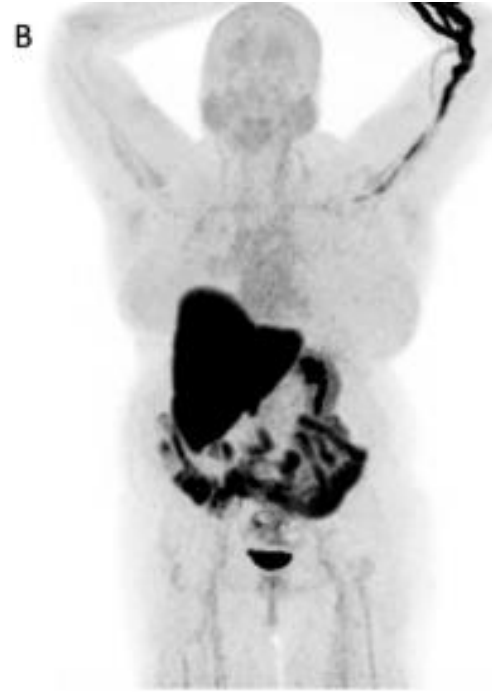

GE HealthCare

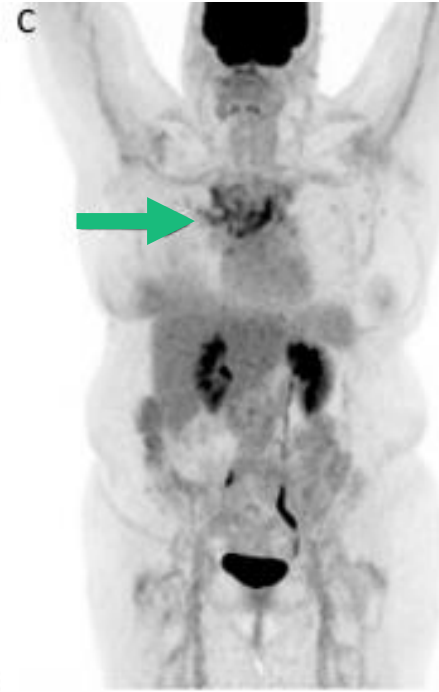Important Safety Information and a link to the full prescribing information can be found on slides 3-5

© 2025 GE HealthCare. GE is a trademark of
General Electric Company used under trademark license.

FES PET MIP



FDG PET MIP



Interpretation⁶:

- No FES avid disease was seen (B)
- Three months later partial metabolic response on FDG PET (C) was noted with persistent abnormal uptake in mediastinal lymph nodes, sternum, and ribs

Importance⁶:

- Based on the FES PET, she was started on capecitabine

FDG, fluorodeoxyglucose; FES, fluoroestradiol; PET, positron emission tomography; MIP, maximum intensity projection; CT, computed tomography.

Cerianna helps to clarify ER+ status in patient with mixed response



Scan to review
publication abstract

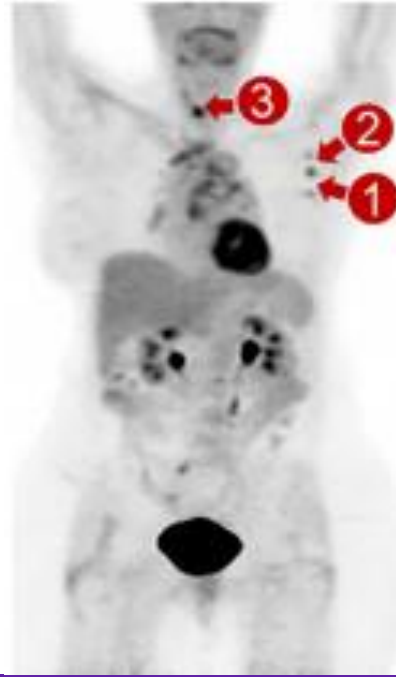
Case details¹¹

- A 72-year-old woman with left breast cancer (intermediate grade, ER+, PR+, HER2-)
- An initial ultrasound-guided core biopsy of the axillary lymph node confirmed ER+ nodal metastasis
- Staging FDG PET that revealed a hypermetabolic left breast lesion and left-sided axillary lymph nodes
- She received letrozole as the neoadjuvant endocrine therapy
- At the completion of her neoadjuvant therapy 6 months after her baseline examination, her restaging FDG PET examination showed a mixed treatment response
 - Subsequent CT-guided core biopsy of the T1 vertebral body lesion confirmed metastatic disease of breast origin but without ER expression

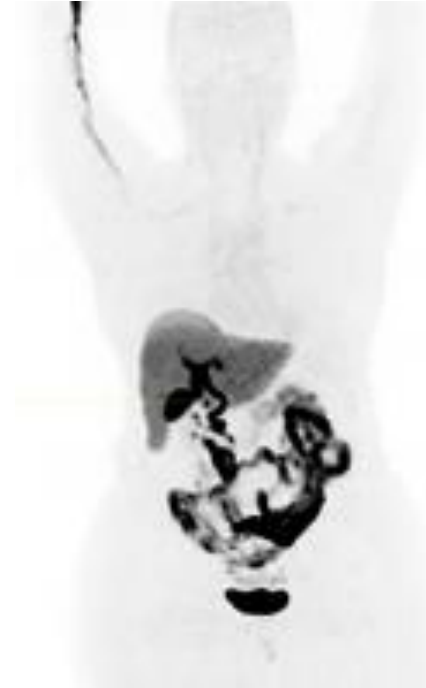Cerianna (FES) PET scan was ordered to clarify ER+ status given the T1 vertebral biopsy was considered to be a false negative result due to decalcified material from the biopsy specimen.

ER, estrogen receptor; FES, fluoroestradiol; CT, computed tomography; PET, positron emission tomography; FDG, fluorodeoxyglucose; PR, progesterone receptor; HER2-, human epidermal growth factor receptor 2 negative; +, positive; T1, first thoracic vertebra.

FDG PET



FES PET



Interpretation¹¹:

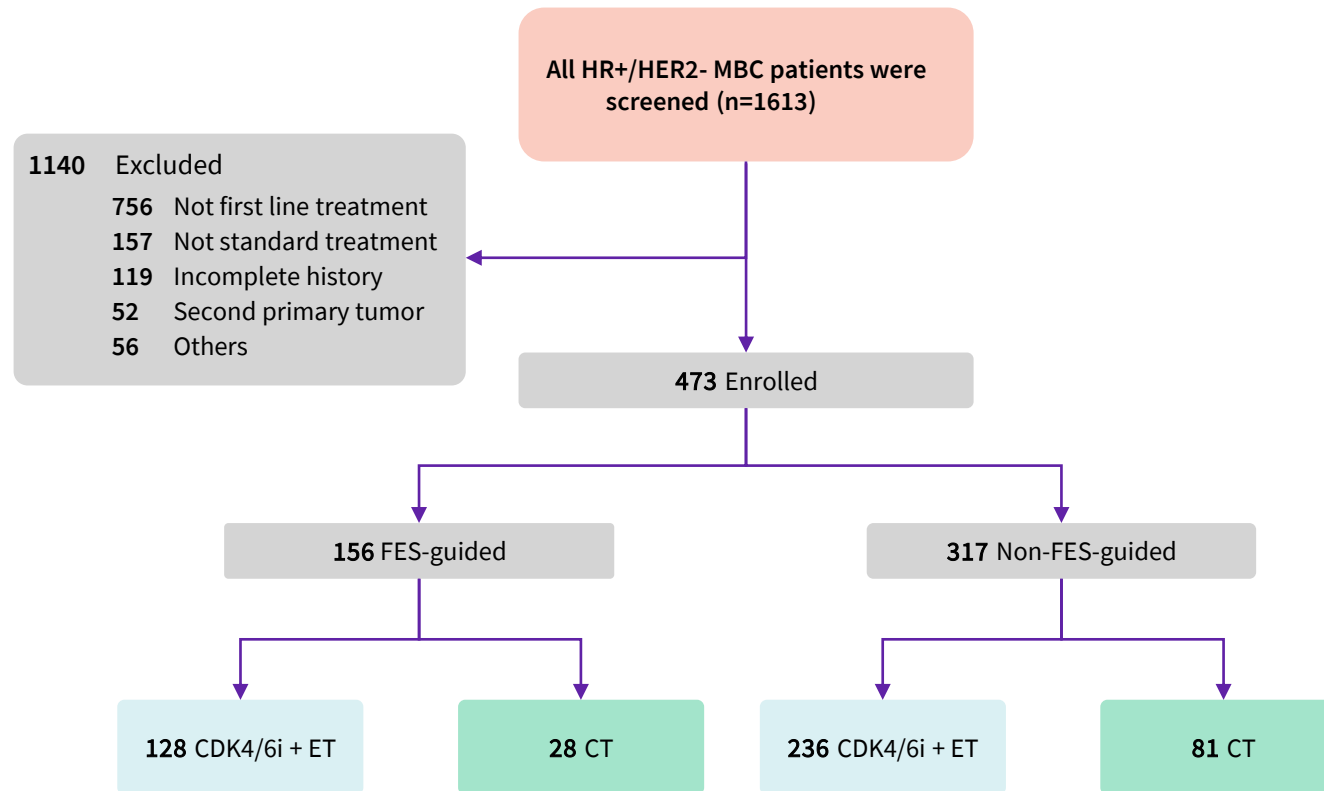
- FDG PET showed decreased size and avidity of the primary breast lesion but increased size and avidity of the metastatic axillary node. Additionally, there was a new hypermetabolic lesion centered in the T1 vertebral body, raising concerns about new osseous metastasis
- FES PET demonstrated the absence of uptake in the T1 vertebral body lesion, as well as the primary breast lesion and metastatic lymph node

Importance¹¹:

- The combination of her disease progression on ET shown on the FDG PET and negative ER expression on bone biopsy and FES PET indicated likely transformation to ER negative disease
 - Thus, endocrine-targeted therapy was discontinued, and this patient was switched to an alternative regimen

FDG, fluorodeoxyglucose; FES, fluoroestradiol; CT, computed tomography; PET, positron emission tomography; ER, estrogen receptor; ET, endocrine therapy; T1, first thoracic vertebra.

Guiding First-Line Therapy in HR+/HER2- Metastatic Breast Cancer



Patient flowchart for inclusion and exclusion. (HR+, Hormone receptor positive; HER2-, human epidermal growth factor receptor 2 negative; MBC, metastatic breast cancer; ET, endocrine therapy; CDK4/6i, CDK4/6 inhibitor; CT, chemotherapy)

Study Design¹²:

- Retrospective study
- 473 patients with HR+/HER2- metastatic breast cancer
- Compared outcomes of patients **screened vs. unscreened** with 18F-FES PET/CT before first-line treatment

Treatment Groups¹²:

- Patients stratified by **FES PET/CT results**: all-FES positive, negative, or heterogeneous

*The F18 fluoroestradiol administered in this study was not equivalent to the FDA-approved formulation of Cerianna (FES) PET.

Results & Clinical Impact

Results¹²:

- **CDK4/6 Inhibitors + Endocrine Therapy Cohort:**
 - FES-screened: mPFS 32.4 months
 - Unscreened: mPFS 17.3 months
 - HR: 0.49, $p < 0.0001$
- **Chemotherapy Cohort:**
 - FES-screened: mPFS 11.38 months
 - Unscreened: mPFS 8.91 months
 - HR: 0.56, $p = 0.026$

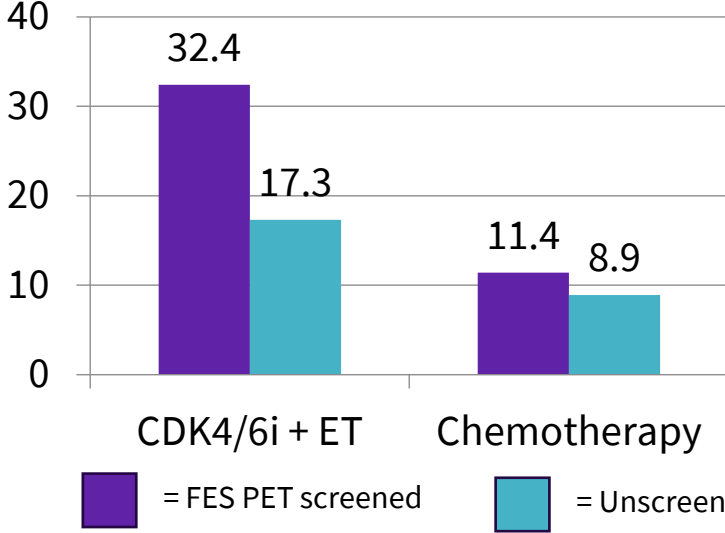
Conclusion¹²:

- In this study, FES-guided treatment significantly improved efficacy in HR+/HER2- MBC patients.

Limitations¹²:

- Retrospective study design and relatively short median follow-up time (22.7 months)
- Patient compliance may have influenced the conclusions of this study
- The sample sizes of some subgroups analyzed in this study might be insufficient

PFS Comparison (Months)



*The F18 fluoroestradiol administered in this study was not equivalent to the FDA-approved formulation of Cerianna (FES) PET.

mPFS, median progression free survival; HR, Hormone receptor positive; FES, fluoroestradiol; HER2-, human epidermal growth factor receptor 2 negative; MBC, metastatic breast cancer; ET, endocrine therapy; CDK4/6i, CDK4/6 inhibitor; CT, chemotherapy

[Back to the top](#)

Key Challenge:

Differentiation between ER+ breast cancer metastases and other tumor types may be complicated with conventional imaging modalities.⁴



FES PET/CT for Characterization of Brain and Leptomeningeal Metastasis in Double Primary Cancer Patient



Scan to review
publication abstract

Case details¹³

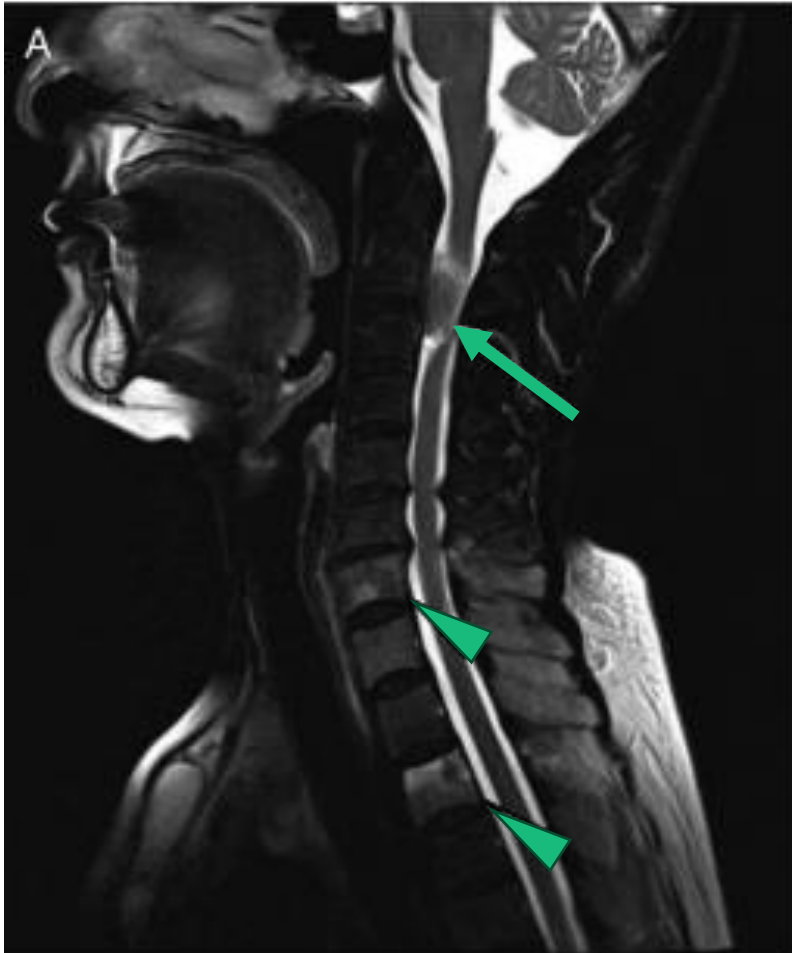- A 72-year-old woman was referred to the orthopedic department for ongoing neck pain with radiating arm pain.
- Her spinal T2-weighted MRI scans showed a suspected metastatic dura-based mass at C2/3 level, along with suspicious bone metastases in cervical, thoracic, and lumbar vertebrae
 - Enhanced brain MRI scans showed enhancing nodules in bilateral cerebral cortices and cerebellum, with the largest nodule in the left precentral gyrus
- She had an approximately 3.2-cm-sized lung nodule at left upper lobe, which was highly suspicious for primary malignancy
- The patient had prior history of breast cancer surgery in 2004 and 2006
- Tumor markers of both CA15-3 (119.4 U/mL) and CEA (20.5 ng/mL) were abnormally elevated at the time of diagnosis

FES PET/CT was performed for whole-body evaluation and further detection of ER+ metastases.

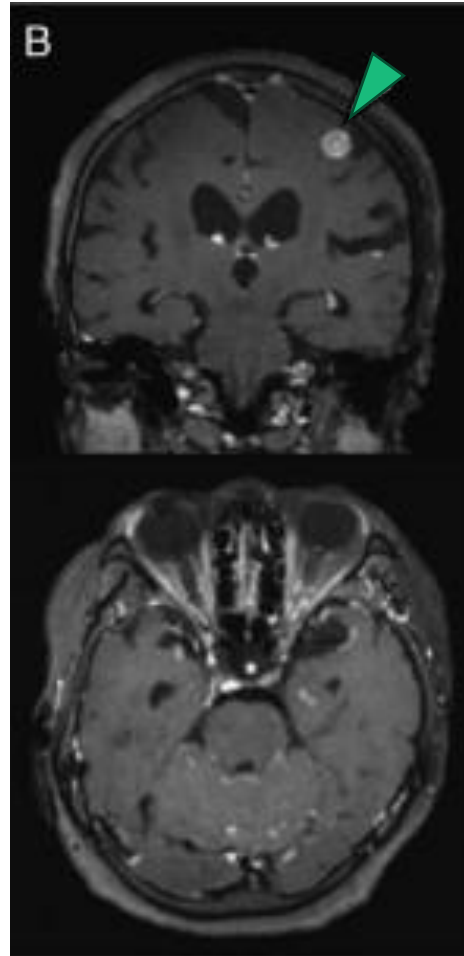
*The F18 fluoroestradiol administered in this study was not equivalent to the FDA-approved formulation of Cerianna (FES) PET.

FES, fluoroestradiol; PET, positron emission tomography; CT, computed tomography; T2, second thoracic vertebra; MRI, magnetic resonance imaging; C2, second cervical vertebra; CA, cancer antigen; CEA, carcinoembryonic antigen, FDG, fluorodeoxyglucose; cm, centimeter, ng, nanogram; mL, milliliter, U, unit.

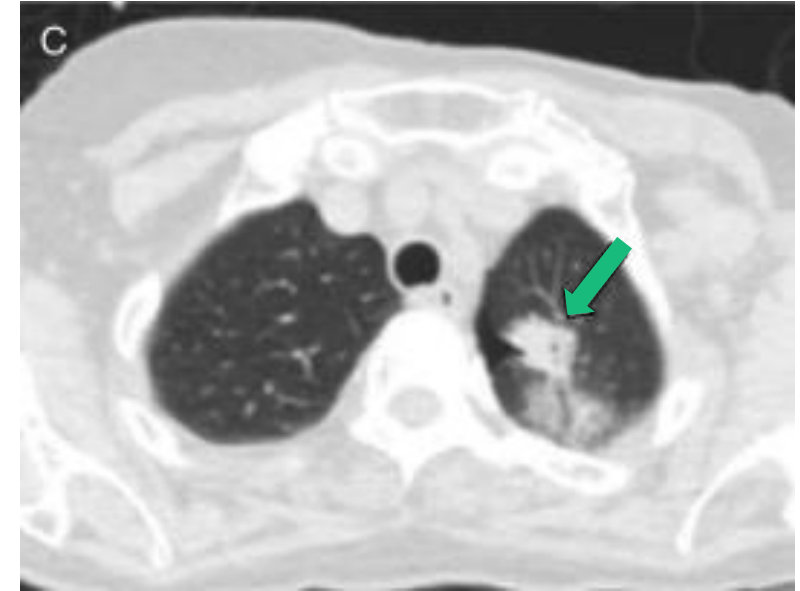
Spinal T2-weighted MRI¹³



Enhanced brain MRI¹³

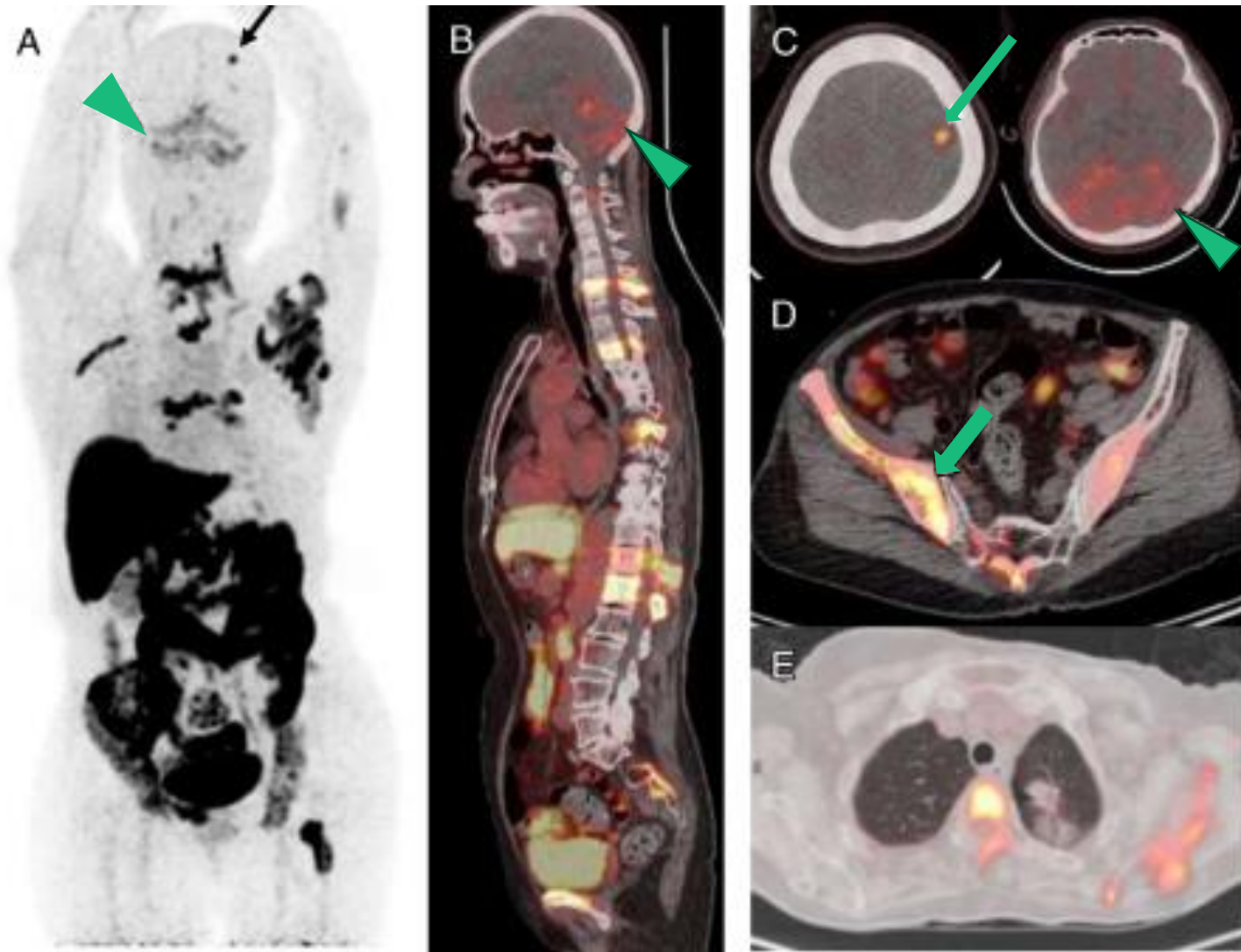


CT¹³



*The F18 fluoroestradiol administered in this study was not equivalent to the FDA-approved formulation of Cerianna (FES) PET.

CT, computed tomography, MRI, magnetic resonance imaging, T2, second thoracic vertebra.



Interpretation¹³:

- A., B., C. MIP and fusion tomographic images of FES PET show focal uptake in the left frontal lobe and diffuse symmetric uptake along meninges of bilateral cerebellar hemispheres
 - Multifocal FES uptake seen in C2 to C3 spinal canal, vertebral column, left scapula, both pelvic bones, sacrum, and left femur
- D. Bone biopsy results of the right pelvic lesion confirmed ER+ breast cancer bone metastasis
- E. No significant FES accumulation was found in the known left upper lobe lung nodule. CT-guided need biopsy identified primary lung adenocarcinoma with negative ER expression

Importance¹³:

- This case demonstrated the clinical utility of FES PET in identifying ER+ CNS metastasis and in detection of distant metastasis when 2 primary cancers are suspected

*The F18 fluoroestradiol administered in this study was not equivalent to the FDA-approved formulation of Cerianna (FES) PET.

MIP, maximum intensity projection; FES, fluoroestradiol; PET, positron emission tomography; MRI, magnetic resonance imaging; C2, second cervical vertebra; C3, third cervical vertebra; ER+, estrogen receptor-positive; FDG, fluorodeoxyglucose; CT, computed tomography, MRI, magnetic resonance imaging; CNS, central nervous system.

Diagnostic Clarity with FES PET



Scan to review
publication abstract

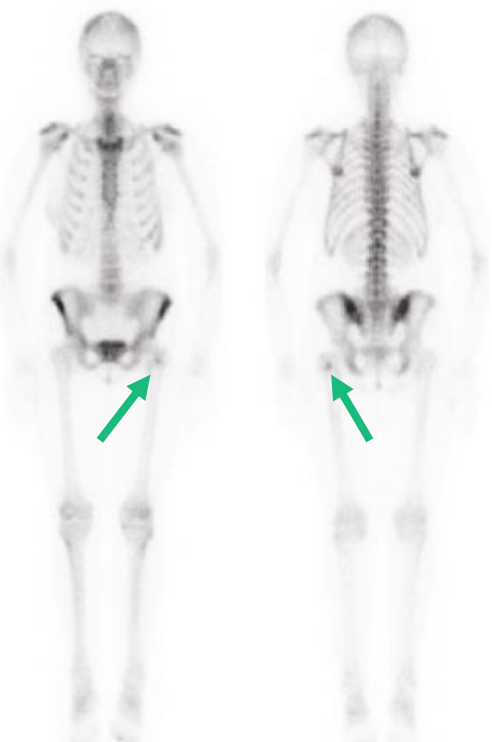Case details⁴

- A 40-year-old female recently diagnosed with ER+ breast cancer
- She underwent a bone scan as part of staging
 - There was abnormal radiotracer uptake in the proximal left femur, raising concern for possible bone metastasis

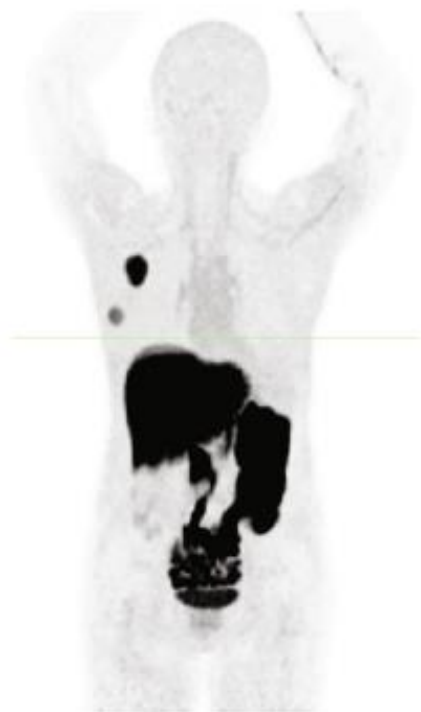FES PET/CT was ordered to evaluate ER expression and assess for possible ER+ metastases.

FES, fluoroestradiol; PET, positron emission tomography; CT, computed tomography; ER, estrogen receptor.

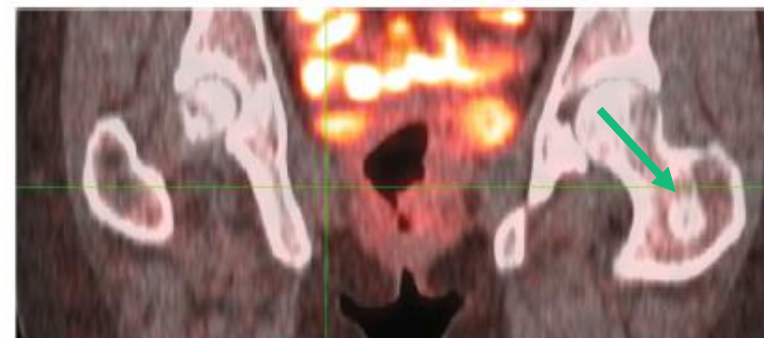
Bone Scan



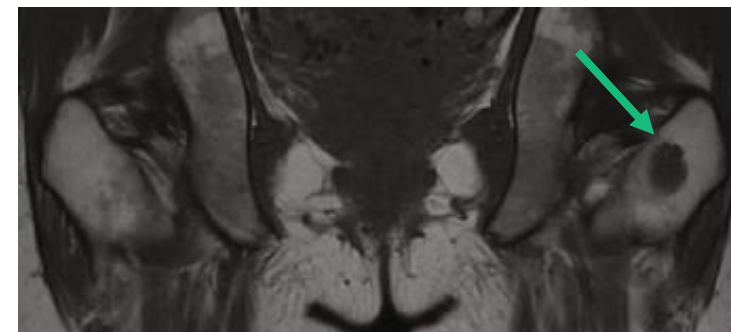
MIP FES PET



Fused FES PET



MRI



Interpretation⁴:

- The bone scan revealed an area of abnormal radiotracer uptake in the proximal left femur
- FES PET/CT revealed no radiotracer uptake in the femoral lesion consistent with the absence of ER expression.
- MRI confirmed the presence of this low-signal-intensity T1 lesion

Importance⁴:

- Given the discordance between the abnormal bone scan and the absence of FES PET uptake, a biopsy of the femoral lesion was performed and confirmed the diagnosis of an enchondroma
- The patient's breast cancer was staged as T2N0M0 due to the absence of metastasis
- **Early integration of FES PET/CT into diagnostic workflows may help distinguish benign from malignant ER+ findings to avoid overtreatment**

MIP, maximum intensity projection; FES, fluoroestradiol; PET, positron emission tomography; CT, computed tomography; ER, estrogen receptor; T1, first thoracic vertebra; T2, second thoracic vertebra; MRI, magnetic resonance imaging

Image Credit: Dawud et al.

Suspicious bone lesion in a patient with newly diagnosis lung primary and history of ER+ breast cancer



Scan to review
publication abstract

Case details¹⁴

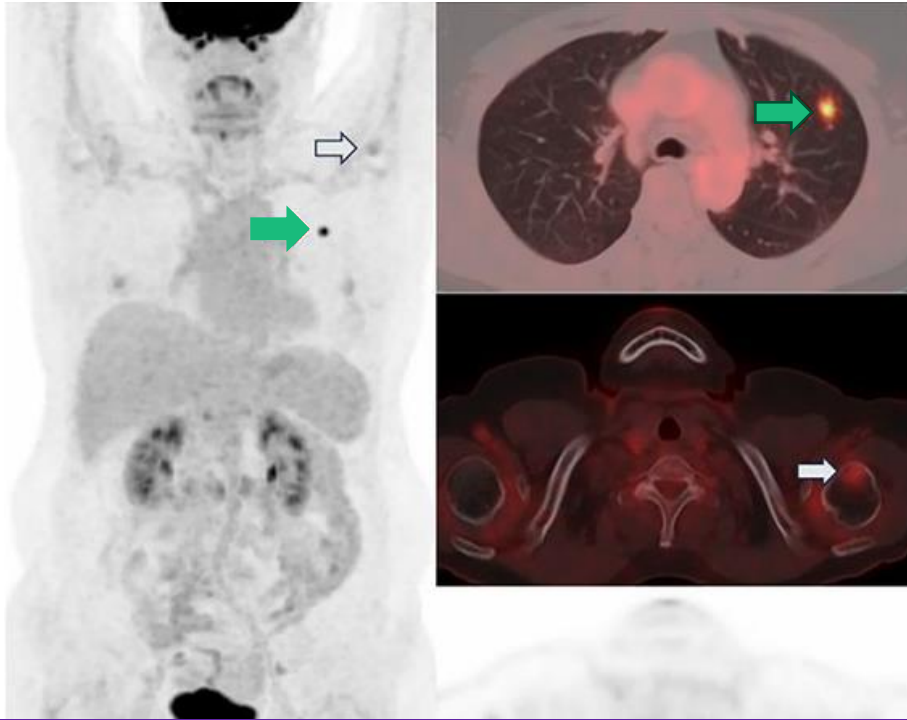
- A 64-year-old woman initially diagnosed with ER+ invasive lobular carcinoma in her left breast
- She underwent breast-conserving surgery followed by radiotherapy and was receiving adjuvant endocrine therapy
- During routine follow-up, a left lung nodule was incidentally detected on chest CT scan and subsequently biopsied, resulting in diagnosis of primary lung cancer
- FDG PET/CT revealed a hypermetabolic nodule in left lung and another hypermetabolic lesion in her left humerus

FES PET/CT was ordered to evaluate ER expression of the left humerus lesion to determine if it was an ER+ metastasis from her breast cancer.

*The F18 fluoroestradiol administered in this study was not equivalent to the FDA-approved formulation of Cerianna (FES) PET.

FES, fluoroestradiol; **PET**, positron emission tomography; **CT**, computed tomography; **FDG**, fluorodeoxyglucose; **ER**, estrogen receptor

FDG PET/CT



Interpretation¹⁴:

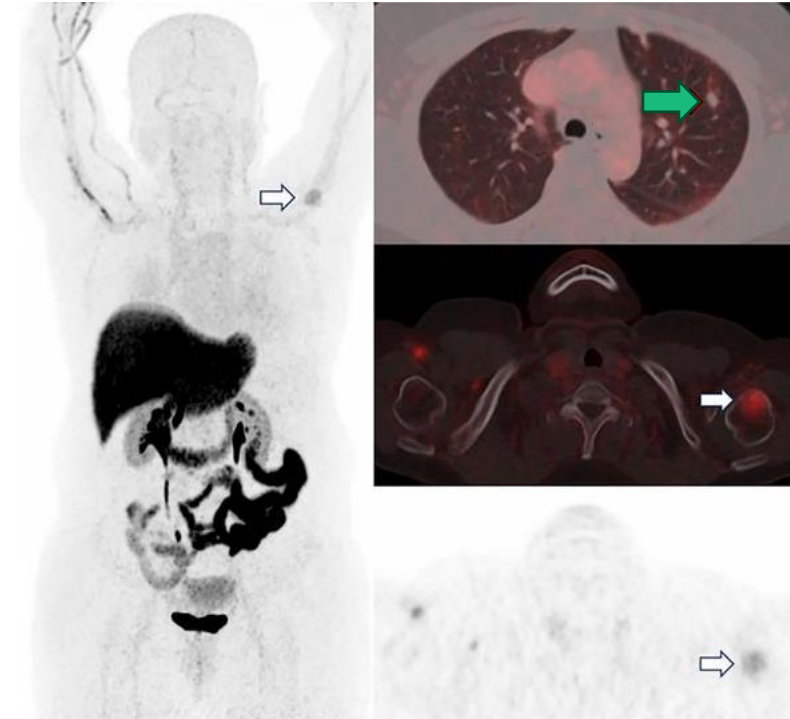
- FDG PET/CT revealed hypermetabolic nodule in left lung (green arrows) and another hypermetabolic lesion at left humerus (white arrows)
- FES PET/CT showed no abnormal uptake by primary lung cancer in left lung (green arrow) and increased uptake in left humeral head (white arrows), indicating ER+ metastasis from breast cancer

*The F18 fluoroestradiol administered in this study was not equivalent to the FDA-approved formulation of Cerianna (FES) PET.

FES, fluoroestradiol; PET, positron emission tomography; CT, computed tomography; FDG, fluorodeoxyglucose; ER, estrogen receptor

Image Credit: Ryu et al.

FES PET/CT



Importance¹⁴:

- Subsequent bone biopsy confirmed metastasis from breast cancer
- **Although palliative chemotherapy for lung cancer was initially considered, management was shifted to surgical removal of lung cancer and palliative radiotherapy for humeral metastasis, along with palliative endocrine treatment with cyclin-dependent kinase 4/6 inhibitor**

Patient with primary gastric cancer and new synchronous ER+ breast cancer found on CT



Scan to review
publication abstract

Case details¹⁵

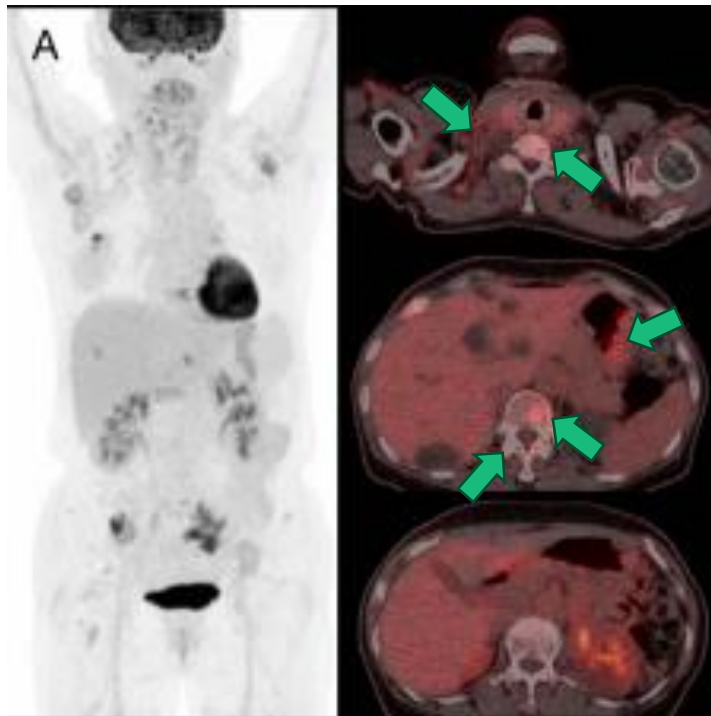
- A 64-year-old woman presented with poorly differentiated carcinoma of the stomach, found during a health check-up
- A chest CT scan revealed a right breast mass, right axillary and supraclavicular lymph nodes, and multiple bone lesions
 - Biopsy confirmed invasive ductal carcinoma in the right breast and metastatic lymph nodes of breast origin in the right axilla
- FDG PET/CT was ordered to assess disease extent

FES PET/CT was ordered to assess ER+ disease extent in this patient with a synchronous gastric cancer.

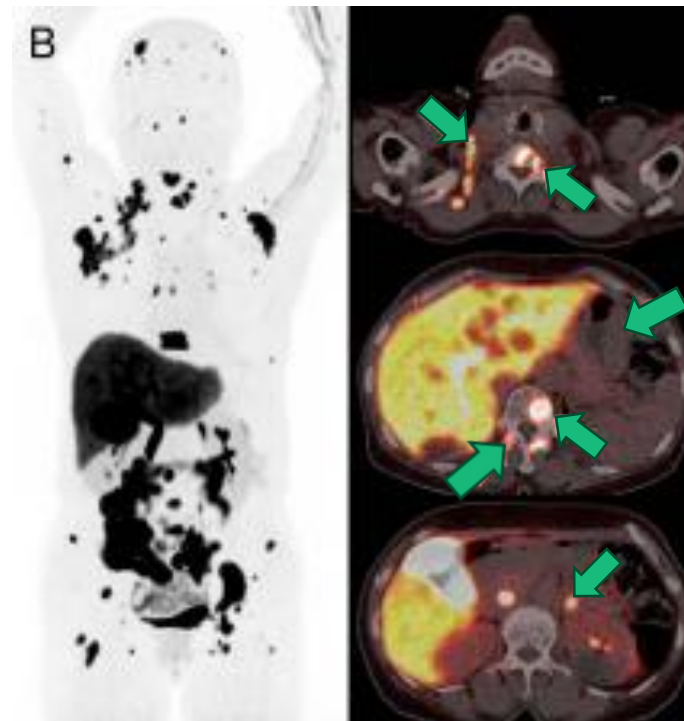
*The F18 fluoroestradiol administered in this study was not equivalent to the FDA-approved formulation of Cerianna (FES) PET.

FES, fluoroestradiol; PET, positron emission tomography; CT, computed tomography; ER, estrogen receptor; FDG, fluorodeoxyglucose.

FDG PET/CT



FES PET/CT



Interpretation¹⁵:

- FDG PET/CT showed a hypermetabolic mass in the right breast, lymph nodes, bones, and stomach
- FES PET/CT revealed FES uptake in both breasts, lymph nodes, bones, and left adrenal gland, but not in stomach

Importance¹⁵:

- Further tissue examination confirmed the stomach lesion as primary gastric cancer
- **Overall, FES PET/CT detected ER+ metastatic lesions and helped distinguish metastases from synchronous gastric cancer in this patient**

*The F18 fluoroestradiol administered in this study was not equivalent to the FDA-approved formulation of Cerianna (FES) PET.

FES, fluoroestradiol; PET, positron emission tomography; CT, computed tomography; ER, estrogen receptor; FDG, fluorodeoxyglucose.

Image Credit: Shin et al.

Key Challenge:

Differentiation of viable ER+ neoplasm from other tumor types and benign processes such as radiation sequelae in patients with known or suspected breast cancer brain metastases may be difficult, especially if biopsy is not feasible⁵.



FES PET in ER+ Breast Cancer Brain Metastases

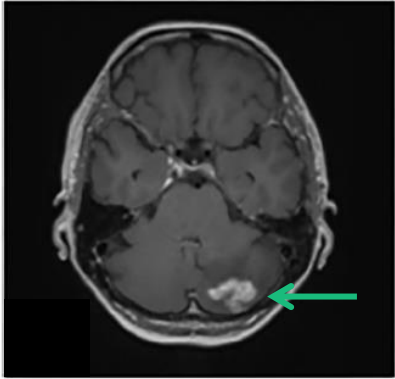
Case details⁵

- 64-year-old female with history of ER > 50%, PR < 50%, HER2 3+ invasive ductal carcinoma
- Two years after the initial treatment, surveillance imaging revealed left cerebellar and right frontal brain metastases
 - She underwent fractionated RT and systemic therapy
- Six months later, MRI demonstrated mild increase in size of the left cerebellar lesion
 - FDG PET/CT demonstrated intense FDG avidity along the posterolateral aspect of the lesion, with intermediate avidity along the anterior aspect, and none to minimum avidity along the medial aspect
 - The enhancing high right frontal lesion also demonstrated increase in size, with no associated increase in FDG avidity

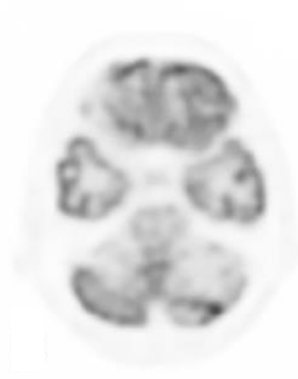
FES PET was ordered as part of a clinical trial to assess if the areas of FDG uptake were more likely related to ER+ breast cancer vs. radiation sequelae.

FES, fluoroestradiol; PET, positron emission tomography; CT, computed tomography; ER+, estrogen receptor positive; PR, progesterone receptor; HER2, human epidermal growth factor receptor 2; MRI, magnetic resonance imaging; FDG, fluorodeoxyglucose; RT, radiation therapy.

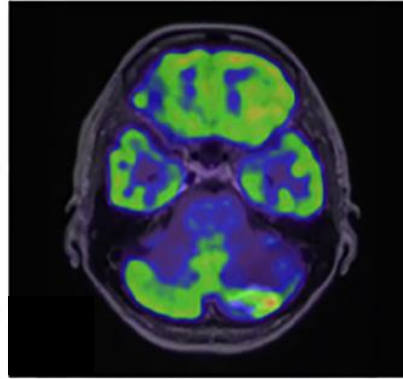
Axial T1 Postcontrast MRI



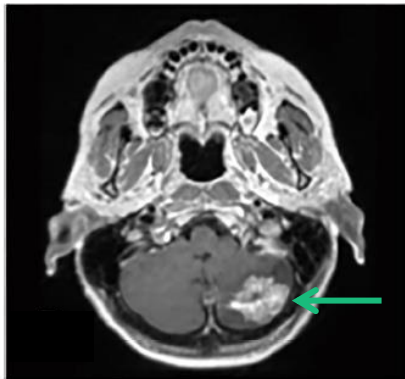
FDG PET



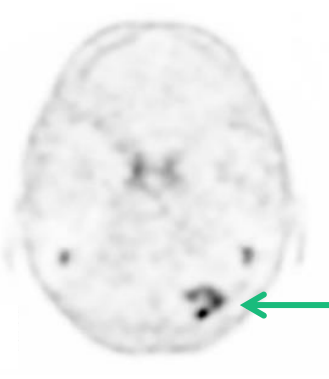
Fused FDG PET/MRI



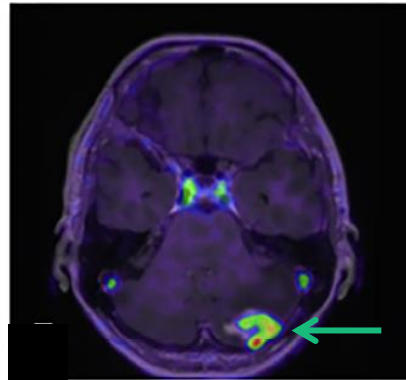
Follow-up Axial T1 Postcontrast MRI



FES PET



Fused FES PET/MRI



T1, first thoracic vertebra; FES, fluoroestradiol; PET, positron emission tomography; CT, computed tomography; ER+, estrogen receptor-positive; MRI, magnetic resonance imaging; FDG, fluorodeoxyglucose; RT, radiation therapy, BCBM; breast cancer breast metastasis.

Image Credit: Ivanidze et al.

Interpretation⁵:

- Short-interval follow-up MRI and concurrent FES PET/CT demonstrated heterogeneous avidity within the left cerebellar lesion, with moderate avidity of the posterolateral component, mild avidity along the anterior component, and no avidity along the medial component
- Findings were suspicious for viable ER+ neoplasm in the posterolateral and anterior components, and RT-sequela in the medial component
 - She underwent a left suboccipital craniotomy for tumor resection, along with the placement of brachytherapy seeds
 - Surgical pathology demonstrated a combination of ER+ BCBM (80% ER+) and RT sequelae

Importance⁵:

- Fused FES PET/MRI: Provided clear visualization of ER+ tumor areas versus treatment-related changes, aiding in precise clinical decision-making

Suspicious brain lesion, not amenable to biopsy

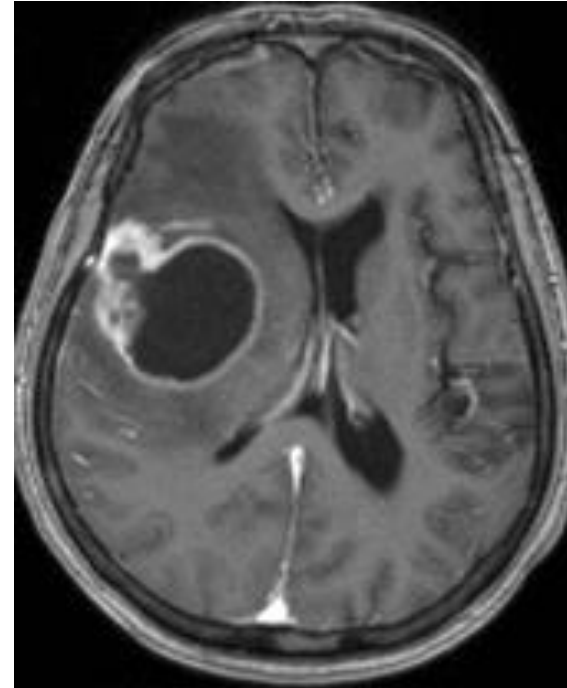


Scan to review
publication abstract

Case details¹⁴

- An 80-year-old woman receiving adjuvant endocrine therapy after mastectomy for ER+ invasive ductal carcinoma in her right breast developed left hemiparesis
- Brain MRI showed rim-enhancing cystic mass in right frontal lobe, suggesting brain metastasis
- Biopsy was not feasible

MRI



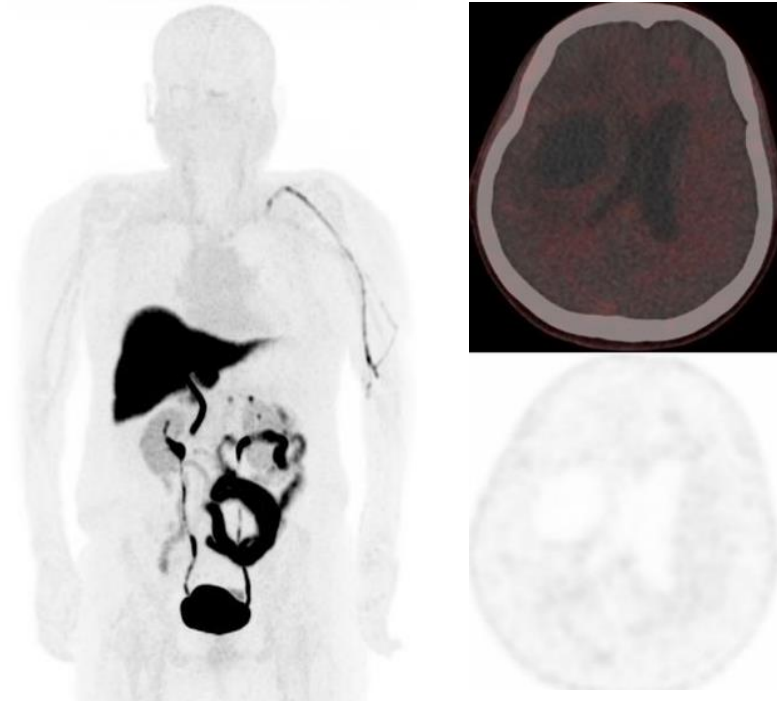
FES PET was performed to evaluate ER+ status of the suspicious brain lesion given biopsy was not possible.

*The F18 fluoroestradiol administered in this study was not equivalent to the FDA-approved formulation of Cerianna (FES) PET.

FES, fluoroestradiol; PET, positron emission tomography; ER+, estrogen receptor positive; MRI, magnetic resonance imaging; FDG, fluorodeoxyglucose.

Image Credit: Ryu et al.

FES PET



Interpretation¹⁴:

- FES PET was performed, which did not show uptake

Importance¹⁴:

- Instead of palliative surgery for a metastatic lesion, curative resection for primary brain tumor was performed because of FES PET findings
 - Surgical specimen confirmed diagnosis of glioblastoma

*The F18 fluoroestradiol administered in this study was not equivalent to the FDA-approved formulation of Cerianna (FES) PET.

FES, fluoroestradiol; PET, positron emission tomography; ER+, estrogen receptor positive; MRI, magnetic resonance imaging.

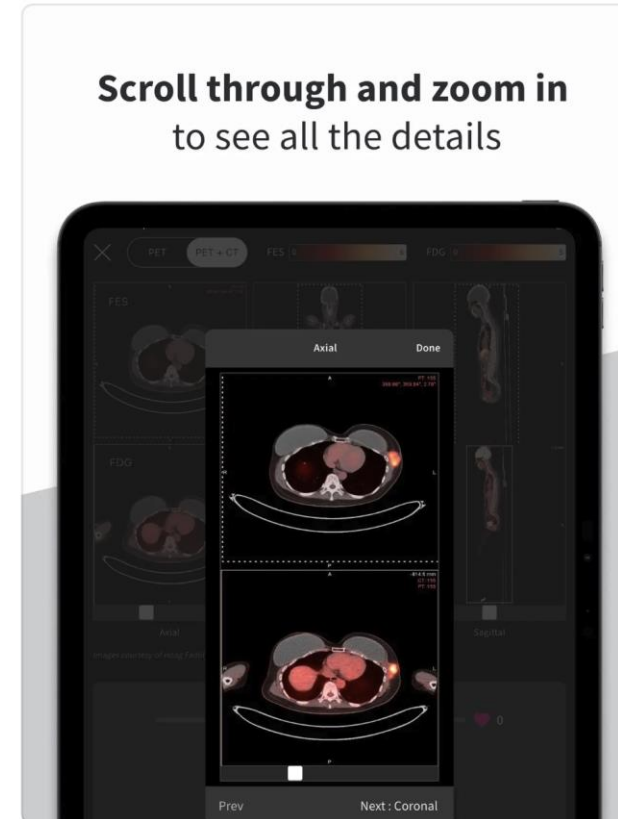
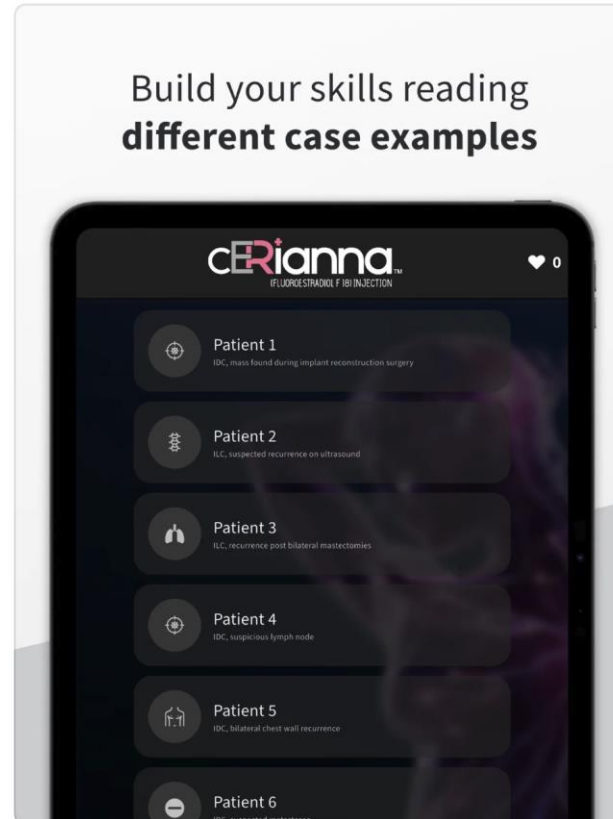
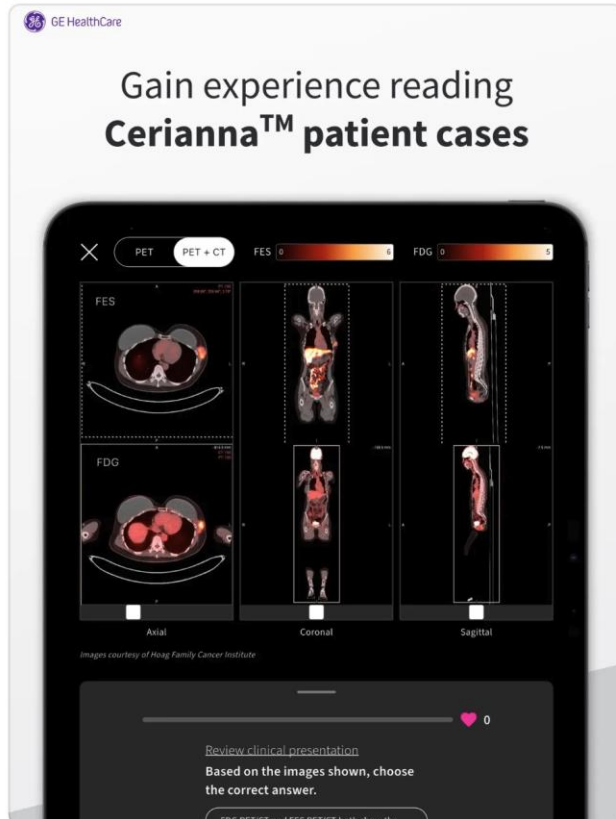
Image Credit: Ryu et al.

[Back to the top](#)

Tools and resources

CeriannaView mobile app

CeriannaView is an innovative educational app designed for oncologists and nuclear medicine physicians to enhance their understanding of Cerianna (FES) PET imaging and its applications in ER+ breast cancer patients. The app provides a comprehensive platform to explore and learn from a curated collection of interesting Cerianna (FES) PET patient exams, alongside their corresponding standard of care images.



Apple App Store



Google Play Store

FES, fluoroestradiol; PET, positron emission tomography; ER+, estrogen receptor positive.

Reader Resources

Interpreter Training

Our educational training platform helps maximize clinical information quality when using Cerianna (FES) PET/CT in metastatic and recurrent breast cancer care. This program is intended for radiologists and nuclear medicine physicians and is led by Dr. Gary Ulaner, Hoag Family Cancer Institute.

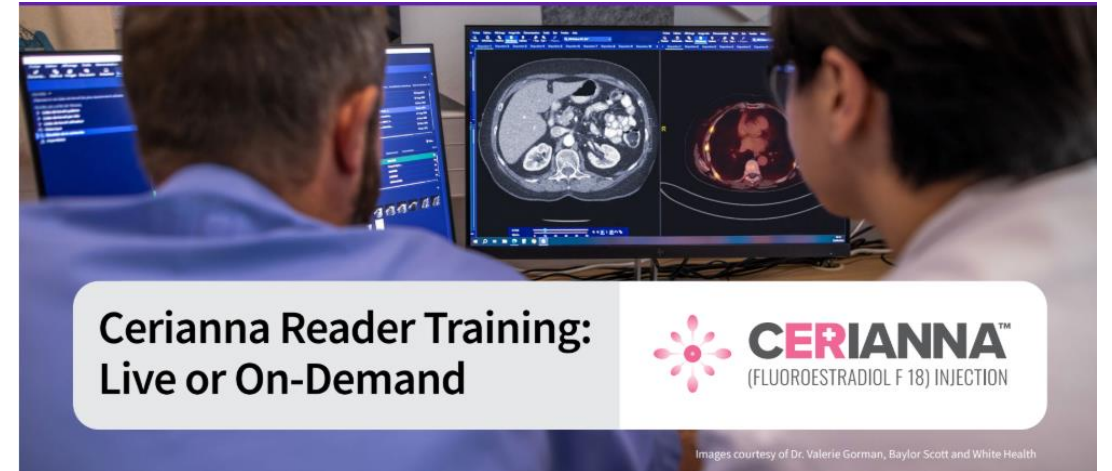Register for
Interpreter training



Advanced interpreter training for complex cases

Unlock expert insights for complex cases with our peer-to-peer advanced reader training program in collaboration with DocPanel. This program is intended for those that have completed the initial interpreter training program.

Register for
advanced reader
training



*DocPanel does not provide medical advice, judgments, or diagnoses. Healthcare providers and their institutions are solely responsible for all patient-related decisions, including image capture, interpretation, diagnosis, treatment, and management. Participation is limited to three program sessions per healthcare provider.



Cerianna (FES) PET/CT: A molecular imaging diagnostic for ER+ recurrent/metastatic breast cancer



Scan to review the overview brochure

Key Insights on Diagnostic Accuracy:

- Based on the findings of the impact study, FES PET demonstrated a positive predictive value (PPV) of 93% (87-96) and a negative predictive value (NPV) of 85% (72-92) in predicting ER immunohistochemical (IHC) status¹⁶.

Clinical Applications:

- Discover how FES PET can aid in identifying ER+ lesions when biopsy is not feasible or inconclusive
- Understand how FES PET results can guide treatment decisions, such as endocrine therapy vs. chemotherapy.

CERIANNA™
(FLUOROESTRADIOL F 18) INJECTION

A molecular imaging diagnostic PET agent for recurrent or metastatic ER+ breast cancer patients

Clear diagnosis, more confident treatment

Dr. Cheryl Hahn, Hoag Family Cancer Institute

Insurance support services

The Cerianna (FES) PET Support Center supports the entire reimbursement journey

Services the Support Center provides:

- Benefit investigations
- Billing and coding guidance
- Claims support
- Assistance with prior authorizations, appeals, and medical necessity documentation
- Locating in-network imaging centers to ensure seamless patient access

Scan the QR code to access support through the online portal

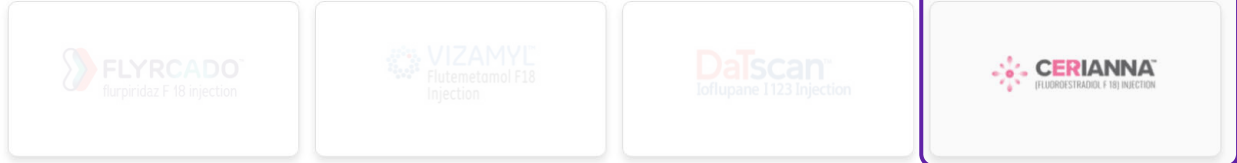


Welcome to the GE HealthCare Digital Enrollment Site

This site offers a convenient way to complete Patient enrollment into the program. The entire process can be completed in a few easy steps, and should only take a few minutes. You will be asked to provide Patient and Provider information, and electronically sign your Consents/Authorizations. You will be able to review and submit the application and print a copy for your records.

Start Enrollment

Select a product below to start enrollment.



Cerianna

FES, fluoroestradiol; PET, positron emission tomography.

References

References

1. Knip JJ, Iqbal R, Bonjer EC, et al. The Diagnostic Accuracy of 18F-FDG PET and 18F-FES PET for Staging Grade 1-2 Estrogen Receptor-Positive Breast Cancer. *Radiology*. 2025;314(3):e241850. doi:10.1148/radiol.241850.
2. Manohar, Poorni M., et al. [18F]-Fluoroestradiol PET (FES-PET) and [18F] Flurodeoxyglucose PET (FDG-PET) Imaging May Aid in Managing Therapy in Patients with Metastatic Lobular Breast Cancer. *Molecular Imaging and Biology*, vol. 27, 2025, pp. 410–420. Springer, doi:10.1007/s11307-025-02015-2.
3. Hartkopf, Andreas D., Eva-Maria Grischke, and Sara Y. Brucker. “Endocrine-Resistant Breast Cancer: Mechanisms and Treatment.” *Breast Care*, vol. 15, no. 4, 2020, pp. 347–354. Karger, doi:10.1159/000508675.
4. Dawud, T. M., and A. T. Dawud. Benign Enchondroma in a 40-Year-Old Female: Emphasizing the Importance of Early 18F-FES PET/CT Utilization." *Case Reports in Radiology*, 2025, Article ID 9992200. Hindawi, <https://doi.org/10.1155/crra/9992200>.
5. Ivanidze et al. [18F]-Fluoroestradiol (FES) brain PET in the evaluation of patients with estrogen receptor positive breast cancer and known or suspected brain metastases. *Eur J Radiol*. 2024 Dec;181:111791. doi: 10.1016/j.ejrad.2024.111791. Epub 2024 Oct 15. PMID: 39423781.
6. O’Brien, Sophia R., et al. Update on 18F-Fluoroestradiol. *Seminars in Nuclear Medicine*, vol. 54, no. 1, 2024, pp. 1–10. Elsevier, doi:10.1053/j.semnuclmed.2024.09.001.
7. Ulaner, Gary A., et al. Appropriate Use Criteria for Estrogen Receptor-Targeted PET Imaging with 16 α -18F-Fluoro-17 β -Fluoroestradiol. *Journal of Nuclear Medicine*, vol. 61, no. 9, 2020, pp. 1339–1346. Society of Nuclear Medicine and Molecular Imaging, doi:10.2967/jnumed.120.245316.
8. Rehman S, Edmonds CE, Mankoff DA, Pantel AR, O’Brien SR. Upstaging of Invasive Lobular Cancer With FES PET/CT. *Clin Nucl Med*. 2024;00:00–00. doi:10.1097/RLU.0000000000005465
9. Ulaner GA, Jhaveri K, Chandarlapaty S, et al: Head-to-head evaluation of (18)F-FES and (18)F-FDG PET/CT in metastatic invasive lobular breast cancer. *J Nucl Med* 62:326-331, 2021
10. Bodapati, Sandhya, et al. "18F-FES PET/CT Improves the Detection of Intraorbital Metastases in Estrogen-Receptor-Positive Breast Cancer: Two Representative Cases and Review of the Literature." **Tomography**, vol. 8, no. 2, 2022, pp. 1060–1065. <https://doi.org/10.3390/tomography8020086>.
11. Zhou, W., et al. (2024). Estrogen receptor–targeted PET imaging for breast cancer. *Radiology*, 312(2), e240315. <https://doi.org/10.1148/radiol.240315>
12. Xie Y, Chen Y, Liu C, et al. 18F-FES PET/CT for guiding first-line treatment in patients with HR+/HER2– metastatic breast cancer: impact on progression-free survival. *Eur J Nucl Med Mol Imaging*. 2025. doi:10.1007/s00259-025-07459-w
13. Lee, Y., Yoo, I. R., & Ha, S. (2022). 18F-FES PET/CT for characterization of brain and leptomeningeal metastasis in double primary cancer patient. **Clinical Nuclear Medicine**, 47(8), e554–e556. <https://doi.org/10.1097/RLU.0000000000004197>
14. Ryu et al. Impact of 18F-FES PET/CT on Clinical Decisions in the Management of Recurrent or Metastatic Breast Cancer. *Journal of Nuclear Medicine* October 2024, jnumed.124.267913; DOI: <https://doi.org/10.2967/jnumed.124.267913>.
15. Shin E, Han S, Ryu J, et al. Diagnostic Accuracy of 18F-FES PET/CT for the Detection of Recurrent and Metastatic Breast Cancer. *Clinical Nuclear Medicine*. 2024;00(00):1–7. doi:10.1097/RLU.0000000000005447
16. van Geel JJJ, Boers J, Elias SG, et al. Clinical validity of 16 α -[18F] Fluoro-17 β -Estradiol positron emission tomography/computed tomography to assess estrogen receptor status in newly diagnosed metastatic breast cancer. *J Clin Oncol*. 2022;40(31):3642-3652. doi: 10.1200/JCO.22.0040

